

The Positive Effect of *Artemisia judaica* on Immunological and Histopathological Changes in Hepatic Rats

Magbolah Salem Helal Alzahrani*

Received: 03 June 2023 / Received in revised form: 06 September 2023, Accepted: 08 September 2023, Published online: 26 September 2023

Abstract

The immune response is the body's capability to keep itself safe by providing defense against potentially dangerous substances. It includes specific responses to most microbes in addition to specialized and greatly precise responses to a specific offender. Positive immunological and histological alterations in hepatically damaged rats, brought about by *Artemisia judaica*. An animal that was confined to a cage for the experiment. The rats were kept in groups of six and fed a diet that served as a baseline for 7 days before the experiment was conducted. The first group of rats (C-ve) were fed only their usual food for 28 days as a control. To kill off the remaining rats (n=24), carbon tetrachloride (Ccl₄) was injected into their veins. Four groups were given experimental diets containing varied amounts (5, 10, or 15 percent *Artemisia judaica*) and one group was given a diagnosis of the condition but no experimental diet. Findings indicated that 15 percent *Artemisia judaica* resulted in the greatest white blood cell counts in treated groups, whereas 10% of *Artemisia judaica* resulted in the lowest value. The findings also showed when contrasted with (C +ve), *Artemisia judaica* doses of 5 percent and 15 percent provide the greatest significant increases in the lymphocytic transformation index. The study recommended feeding *Artemisia judaica* to enhance immunity and improve the histology of the liver.

Keywords: *Artemisia judaica*, Immunological effect, Histopathological changes, Hepatic rats

Introduction

Artemisia judaica has been used as a treatment for many years. (Olennikov *et al.*, 2018) found that preparations made from different portions of the plant (aerial parts and leaves) were effective in treating a broad variety of conditions, involving gastrointestinal distress, liver malfunction, skin inflammation, and immune system improvement. The Asteraceae family includes the genus *Artemisia*, which has more than 480 species of tiny herbs and/or shrubs. Multiple members of the *Artemisia* genus are utilized to enhance immune function, and several *Artemisia* species have been examined extensively for their potential to cure liver ailments. Anti-inflammatory, antioxidant, antimalarial,

antibacterial, and antiseptic properties have been found in various species of this genus (Abiri *et al.*, 2018). It's a staple of traditional medicine in the Arabian Gulf, where it's utilized for everything from controlling diabetes to killing off parasites (Mesa *et al.*, 2015). *Artemisia judaica* is a fragrant Mediterranean herb that has been utilized medicinally for centuries to cure a wide variety of conditions, including diarrhea, eczema, and psoriasis. This analysis of ArJ essential oil components and their wound-healing potential was conducted by Zuzarte *et al.* (2022). Antifungal, neuroprotective, insecticidal, antimicrobial, anthelmintic, acaricidal, antimalarial, antidepressant, and hepatoprotective are only some of the purported effects of *Artemisia absinthium*. It's used to add flavor to a variety of alcoholic beverages and wines, involving absinthe, bitters, bask, vermouth, and pelinkovac, to name a few. Dyspepsia, loss of appetite, numerous viral disorders, Crohn's disease, and IgA nephropathy are all treated with it (El-Aasr *et al.*, 2022).

An immune response is the body's ability to stay safe by protecting hazardous substances and includes specific responses to a single offender as well as lines of defense against the majority of microbes. Both the innate immune response (which is not very particular) and the adaptive immune response (which is quite specific) fall under this umbrella (Arce-Sillas *et al.*, 2016). Specific lymphocytes and their byproducts (immunoglobulins and cytokines) will be utilized by the adaptive acquired immune response to mount an attack on the invading microbes (Lawrence *et al.*, 2016).

1- Aim of Study

Showed the positive impact of *Artemisia judaica* on immunological & histologic alterations in hepatic rats.

Materials and Methods

Materials

Preparation of *Artemisia judaica*

Artemisia judaica are washed, sliced thinly, and dried in an oven at fifty degrees Celsius for three days before being crushed & ground into a powder.

Experiential Animals

For this research, we utilized 30 male Sprague Dawley albino rats that averaged 150±10 g in weight.

Magbolah Salem Helal Alzahrani*

Department of Biology, Faculty of Science, AL-Baha University, Saudi Arabia.

*E-mail: mshzahrani@bu.edu.sa



Biological Experiment

Rats' Normal Diet

There were 10 percent casein, 0.25 percent choline chloride, 1 percent vitamins, 5 percent cellulose, 10 percent maize oil, 4 percent salt, 0.3 percent methionine, and 69.5 percent corn starch in the basil diet (Morsi, 1992).

CaCO₃ (600 mg), K₂HPO₄ (645 mg), MgSO₄·2H₂O (204 mg), CaHPO₄·2H₂O (150 mg), CuSO₄·5H₂O (0.06 mg), ZnCl₂ (0.5 mg), MnSO₄·4H₂O (10 mg), Fe (C₆H₅O₇) 26H₂O (55 mg), NaCl (334 mg), and KI (1.6 mg) were all part of the study's base diet (Hegsted *et al.*, 1941).

The standard test diet included Vitamin A (200 Iu), Vitamin K (0.50 Iu), Vitamin D (100 Iu), Calcium pantothenic acid (0.40 mg), Para-aminobenzoic acid (0.02 mg), Pyridoxine (1.00mg), Vitamin E (10 Iu), Thiamin (0.50 mg), Choline chloride (200 mg), Folic acid (0.02 mg), Niacin (4.00 mg), Inositol (24 mg), Vitamin B12 (2.00 g) (Campbell, 1963).

Diet Experiment

Table 1 presents the experimental diet, which is based on the standard diet plus a 10 percent supplement of plant powders.

Table 1. The make-up of both the standard and the experimental diets.

| Component (g) | Basal diet | 5% <i>Artemisia judaica</i> | 10% <i>Artemisia judaica</i> | 15% <i>Artemisia judaica</i> |
|-------------------------|------------------|-----------------------------|------------------------------|------------------------------|
| Test ingredients | --- | 5 | 10 | 15 |
| Casein | 20 | 20 | 20 | 20 |
| Corn oil | 4.7 | 4.7 | 4.7 | 4.7 |
| Mineral mix | 3.5 | 3.5 | 3.5 | 3.5 |
| Vitamin mix | 1 | 1 | 1 | 1 |
| Cellulose | 5 | 5 | 5 | 5 |
| Choline chloride | 2 | 2 | 2 | 2 |
| Sucrose | 10 | 10 | 10 | 10 |
| Corn starch | Up to 100 | Up to 100 | Up to 100 | Up to 100 |

Carbon Tetrachloride (Ccl₄)

Ccl₄ was given by El-Gomhoria Company for Chemical Industries, a Cairo, Egypt-based chemical supplier. (Passmore & Eastwood, 1986) stated it was sold in one-liter white plastic water bottles and disseminated as a dangerous material component for liver sickness. Throughout the initiation, it is diluted with paraffin oil purchased from a pharmacy.

Rats

Male Sprague-Dawley albino rats weigh in at a healthy 150-160 g when fully grown. The animals spent 14-16 weeks in the Animal Laboratory before being moved. The animal enclosures were spotless, made of plastic, and covered with stainless steel. For seven days before the trial, the rats were given the standard food. so that they could get used to it. Ad libitum water was available from a smallmouth bottle attached to a plastic tube & a metallic tube at the mouth. For seven days beforehand the start of the study, the rats had been utilized to a 12-hr light/12-hr dark cycle, as was previously mentioned.

Liver Toxicity in Rats Artificially Induced

(Jayasekhar *et al.*, 1997) To produce chronic liver damage in male albino rats, we employed intramuscular injections of Ccl₄ dissolved in paraffin oil with a volume-to-volume ratio of 50% and gave these injections Two times a week for a total of 14 days. Afterward the administration of Ccl₄, blood samples were drawn using the retro-orbital method to verify the existence of liver damage & evaluate liver function.

Animal Groups and the Methodology of the Experiment

There were 6 rats in each group, and each group was split into seven subgroups. The following categories of rats made up the groups:

- G1: The normal rats served as the control group and were given a standard diet for 28 days without receiving any kind of therapy.
- G2: Liver-toxic rats were retained as control negatives & given a baseline diet for 28 days without any therapy being administered to them.
- G3: Rats with liver toxicity that were given a standard diet with an additional 5% of *Artemisia judaica*.
- G4: Rats with liver toxicity that were given a standard diet with an addition of 10 percent *Artemisia judaica*.
- G5: Rats with liver toxicity that were given a standard diet with an addition of 15 percent *Artemisia judaica*.

Biological Evaluation

The amount of food that was ingested daily was tracked during the whole 28-day trial, and weekly measurements of body weight were taken. Calculations were done to determine the body weight growth (B.W.G.%), the feeding efficiency ratio (F.E.R.) & the organ weight (Chapman *et al.*, 1959).

Blood Sampling

Following 12 hours without eating, blood samples were taken after the research. Blood samples were gathered using the retro-orbital technique in extremely specialized glass tubes before being allowed to clot for 30 minutes at room temperature in a water bath (37 °C). Prior to the glucose test, to isolate the serum, samples of

blood were centrifuged for ten minutes at 3000 revolutions per minute. Aspiration of the residue was placed in sterilized polypropylene tubes with secure caps and frozen at -20 degrees Celsius until analysis.

According to (Drury & Wallington, 1980), 10% formalin was used to preserve the liver, heart, kidney, and spleen after they were removed, rinsed in salt solution, weighed & then stored.

Immunologic Analysis

Transformation Analysis of Lymphocytes. Boyum (1968) And Burrels and Wells (1977) Both Study Lymphocytes

Heparinized blood was delicately deposited onto the surfaces of the lymphocyte separation medium utilizing sterile Pasteur pipettes. A 50 ml sterile polystyrene centrifuge tube filled with Ficoll hypaque (1.1).

Histopathological Examination

To preserve the liver tissue, samples were taken upon animal sacrifice at the conclusion of the study, fixed in ten percent neutral formalin, ethyl alcohol-dried, cleaned in xylene & embedded in paraffin wax. Eosin & hematoxylin were utilized to stain slices that were 4-6 microns in thickness (Carleton, 1979).

Statistical Analysis

The statistical analysis was computed utilizing a one-way classification, the analysis of variance (ANOVA), and the least significant difference (LSD) (Snedecor & Cochran, 1967).

Results and Discussion

The primary objective of this research was to show the positive influence of *Artemisia judaica* on histopathological & immunological alterations in rats with hepatic conditions.

Immunologic Changes

Effect of Different Levels of Artemisia judaica on Red Blood Cell and White Blood Cell Levels of Obese Rats

Data provided in **Table 2** display the impacts of different levels of *Artemisia judaica* on red blood cell and white blood cell levels of hepatic rats. According to the findings, the negative control (C-ve) group had the largest number of red blood cells, even though the positive control group (C +ve) had the fewest. The average was 4.85, while the median was 3.05 106 cells/mm3.

In contrast, the greatest red blood cell levels of treated groups were verified for 15% *Artemisia judaica*, whereas the least value was verified for 5% *Artemisia judaica* with significant variances. The mean values were 4.45 and 3.53 106/mm3, respectively.

The data also displayed that the C +ve group had the largest number of white blood cells, even though the C-ve group had the fewest. Typically, 8.20 and 5.50 x 103 cells per mm³ were utilized.

In contrast, the greatest white blood cell levels of groups that were given treatment (hepatic groups) verified for 5% *Artemisia judaica*, even though the fewest value verified for 10% *Artemisia*

judaica. The mean values were 6.80 and 5.90 103/mm3, respectively.

Table 2. The effects of different levels of *Artemisia judaica* on red blood cell and white blood cell levels of hepatic rats

| Groups | Parameters | |
|------------------------------|-------------------------|-------------------------|
| | RBC(106/mm3) | WBC(103/mm3) |
| Control (-) | 4.85± 0.21 ^a | 5.50± 0.60 ^c |
| Control (+) | 3.05±0.10 ^c | 8.20± 0.30 ^a |
| 5% <i>Artemisia Judaica</i> | 3.53± 0.80 ^b | 6.80± 0.40 ^b |
| 10% <i>Artemisia Judaica</i> | 3.95± 0.50 ^b | 5.90± 0.10 ^c |
| 15% <i>Artemisia Judaica</i> | 4.45± 0.50 ^a | 6.20± 0.20 ^b |

Means in the same column with different litters are significantly different (P <0.05).

Result of Different Levels of *Artemisia judaica* on Hemoglobin and Platelet Levels of Hepatic Rats

Data provided in **Table 3** illustrates the influence of varying levels of *Artemisia judaica* on hemoglobin and platelet levels of hepatic rats.

The greatest disparities in hemoglobin levels were seen amongst the C-ve group & the C +ve group. The average was 13.54 and the median was 9.50 g/dl.

However, there were statistically significant variations in the hemoglobin levels among the treated groups (hepatic groups), with the greatest levels reported for 15% *Artemisia judaica* and the lowest levels recorded for 5% *Artemisia judaica*. The average was 12.80, while the median was 11.58 g/dl.

The data also illustrated that the C +ve group had the largest number of platelets, while the C-ve group had the lowest. A median of 235.0 and a median of 205.0 1 06/mm3 were obtained.

However, there were statistically significant variances between the maximum platelet levels obtained in treated groups (hepatic groups) and the lowest value observed for 15 percent *Artemisia judaica*. Both averaged out to be rather high, at 225.0 and 208.0 106/mm3, respectively.

Table 3. Show the impact of different level of *Artemisia judaica* on hemoglobin and platelet levels of hepatic rats.

| Groups | Parameters | |
|------------------------------|---------------------------|---------------------------|
| | Hemoglobin (g/dl) | platelet levels (106/mm3) |
| Control (-) | 13.54 ^a ± 0.30 | 205 ^a ± 0.60 |
| Control (+) | 9.50 ^c ±0.90 | 235 ^a ± 0.50 |
| 5% <i>Artemisia Judaica</i> | 11.58 ^b ± 0.60 | 225 ^b ± 0.20 |
| 10% <i>Artemisia Judaica</i> | 12.30 ^b ± 0.40 | 216 ^c ± 0.50 |
| 15% <i>Artemisia Judaica</i> | 12.80 ^a ± 0.10 | 208 ^c ± 0.40 |

The Effect of Different Levels of *Artemisia Judaica* on Lymphocytic Transformation Index in Hepatic Rats

Data provided in **Table 4** illustrates the transformation of lymphocytes was 1.24±0.12 percent less common in untreated Ccl4-injected rats (C +ve) than in normal rats (C -ve)

($1.97 \pm 0.12\%$). Results show that an indicator of the lymphocytic transformation process in the blood of hepatic rats is much lower than that of (C -ve) normal rats. When contrasted with the control group (C +ve), the lymphocytic transformation index rose significantly in all treatment groups. Ccl4-poisoned rats fed the same diet of 5% and 15% When contrasted with (C +ve), *Artemisia judaica* demonstrated a statistically significant rise of 1.71 ± 0.13 and $1.74 \pm 0.08\%$, respectively. When compared to the findings of (Zuzarte & Salgueiro, 2022), who analyzed its impacts in traditional medicine, the Mediterranean aromatic herb *Artemisia judaica* was employed for the treatment of gastrointestinal disorders, skin problems, atherosclerosis, and as an immunostimulant. The purpose of this research was to characterize the components of ArJ essential oil and to examine their wound-healing activities.

Table 4. Show the result of different levels of *Artemisia judaica* on lymphocytic transformation index in hepatic rats.

| Groups | Parameters | |
|------------------------------|-----------------------------|-------|
| | Lymphocytic transformation | |
| | Index (%) Mean \pm S.E | IR• |
| Control (-) | 1.97 ± 0.12 a | 58.87 |
| Control (+) | 1.24 ± 0.12 e | - |
| 5% <i>Artemisia Judaica</i> | 1.71 ± 0.13 b | 37.90 |
| 10% <i>Artemisia Judaica</i> | 1.64 ± 0.05 c | 32.26 |
| 15% <i>Artemisia Judaica</i> | 1.74 ± 0.08 b | 40.32 |

Values denote arithmetic means \pm Standard error of the mean.

Means with different letters (a, b,c,d) in the same column differ significantly at $p \leq 0.05$

using a one-way ANOVA test, while those with similar letters are non-significant.

IR•: Means increase ratio of control positive group.

Histopathological Results

The typical histological structure of the hepatic lobule was seen under a microscope in the liver of group 1 animals (**Figure 1**). By contrast, Kupffer cell activation & localized hepatocellular necrosis accompanied by mononuclear inflammatory cell infiltration were detected in the livers of rats in group 2 (**Figure 2**). Meanwhile, Central venous congestion and slight accumulation of certain hepatocytes were seen in group 5 tissue slices (**Figure 3**).

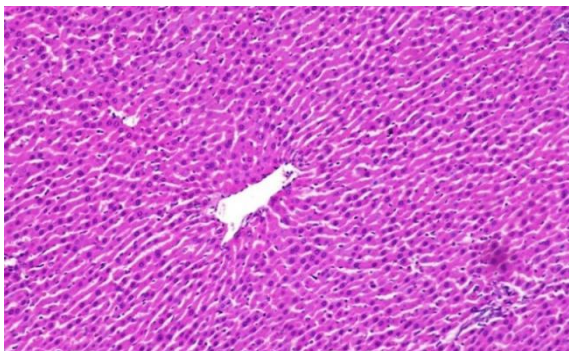


Figure 1. Liver from the standard control rat displaying the histologically typical structure of the hepatic cells (HCs), central vein (CV), and portal area (arrow). (H&E, X200).

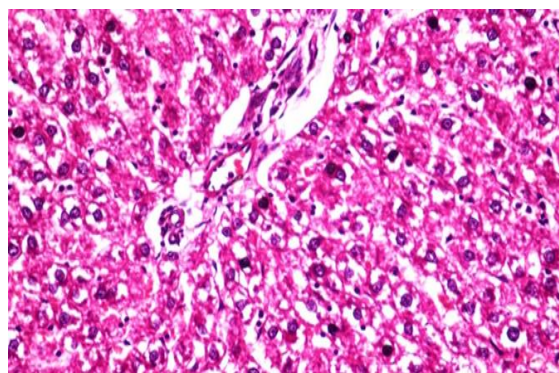


Figure 2. Liver of C +ve revealed Kupffer cells activation & focal hepatocellular necrosis related to mononuclear inflammatory cells infiltration. (H&E, X200)

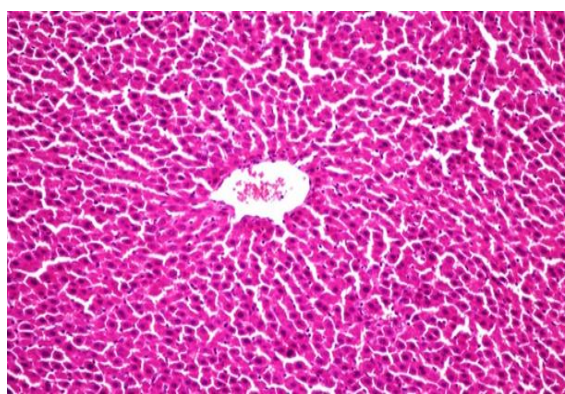


Figure 3. Group 5 liver revealed CV congestion and mild hepatocyte accumulation (H&E, X200).

Conclusion

The results showed that *Artemisia judaica* has a strong effect in enhancing immunity.

Improvement rate increased in the group containing 15% *Artemisia judaica*, because it contains sterol and phenolic acids which consider antioxidant that might increase antioxidant enzyme activities such as superoxide dismutase, catalase, and glutathione peroxidase which improves immunity.

Recommendations

1. For hepatic patients, *Artemisia judaica* is recommended to enhance immunity.
2. Different levels of *Artemisia judaica* concentrations can improve the histology of the liver.

Acknowledgments: None

Conflict of interest: None

Financial support: None

Ethics statement: None

References

- Abiri, R., Silva, A. L. M., de Mesquita, L. S. S., de Mesquita, J. W. C., Atabaki, N., de Almeida Jr, E. B., Shaharuddin, N. A., & Malik, S. (2018). Towards a better understanding of *Artemisia vulgaris*: Botany, phytochemistry, pharmacological and biotechnological potential. *Food Research International*, 109, 403-415. doi:10.1016/j.foodres.2018.03.072
- Arce-Sillas, A., Álvarez-Luquín, D. D., Tamaya-Domínguez, B., Gomez-Fuentes, S., Trejo-García, A., Melo-Salas, M., Cárdenas, G., Rodríguez-Ramírez, J., & Adalid-Peralta, L. (2016). Regulatory T cells: molecular actions on effector cells in immune regulation. *Journal of Immunology Research*, 2016, 1720827.
- Campbell, J. A. (1963). Methodology of protein evaluation. In *RGA Nutr. Document R. Led. 37. June meeting, New York* (Vol. 249).
- Carleton, H. (1979). *Histological Techniques*, 4th Ed. London, Oxford, New York, Toronto.
- Chapman, D. G., Castillo, R., & Campbell, J. A. (1959). Evaluation of protein in foods: 1. A method for the determination of protein efficiency ratios. *Canadian Journal of Biochemistry and Physiology*, 37(5), 679-686.
- Drury, R. A., & Wallington, E. A. (1980). *Carlton's Histological Technique*. 5th Ed. Oxford University.
- El-Aasr, M., Attia, G., Alqahtani, M. J., Yassien, R. I., Abo Kamer, A., & Elekhawy, E. (2022). Promising antifungal activity of *Encephalartos laurentianus* de wild against *Candida albicans* clinical isolates: In vitro and in vivo effects on renal cortex of adult albino rats. *Journal of Fungi*, 8(5), 426. doi:10.3390/jof8050426
- Hegsted, D. M., Mills, R. C., Elvehjem, C. A. F., & Hart, E. B. (1941). Choline in the nutrition of chicks. *Journal of Biological Chemistry*, 138, 459-466.
- Jayasekhar, P., Mohanan, P. V., & Rathinam, K. (1997). Hepatoprotective activity of ethyl acetate extract of *Acacia catechu*. *Indian Journal of Pharmacology*, 29(6), 426.
- Lawrence, H., Mawdesley, A. E., Holland, J. P., Kirby, J. A., Deehan, D. J., & Tyson-Capper, A. J. (2016). Targeting Toll-like receptor 4 prevents cobalt-mediated inflammation. *Oncotarget*, 7(7), 7578.
- Mesa, L. E., Lutgen, P., Velez, I. D., Segura, A. M., & Robledo, S. M. (2015). *Artemisia annua* L., potential source of molecules with pharmacological activity in human diseases. *American Journal of Phytomedicine and Clinical Therapeutics*, 3(5), 436-450.
- Morsi, A. E. (1992). Your Health and Healing between your Hands in Herbs. *Arabic, Egypt*.
- Olenikov, D. N. (2018). Phytoecdysteroids and flavonoids from *Gastrolychnis tristis*. *Chemistry of Natural Compounds*, 54, 204-206.
- Passmore, R., & Eastwood, M. (1986). *Human Nutrition and dietetics*. Eight edition: Longman Group UK LTD. Churchill Livingstone.
- Snedecor, G. W., & Cochran, W. G. (1967). *Statistical Methods*. 6th Ed. Iowa State University Press. Ames. Iowa. The USA.
- Zuzarte, M., & Salgueiro, L. (2022). Essential oils in respiratory mycosis: A review. *Molecules*, 27(13), 4140. doi:10.3390/molecules27134140