

Immunolocalization of Adrenal Estrogen Receptors (ERs) In Pregnant Rabbits Treated with Organic Extract of *Bunium incrassatum*

Naoual Hammoudi, Souad Boulahbel, Sana Chentouh, Yasmina Bentayeb*, Hind Djebaili, Amina Wissame Hadjeris, Nouredine Gherraf

Received: 29 March 2021 / Received in revised form: 08 May 2021, Accepted: 19 May 2021, Published online: 21 June 2021

© Biochemical Technology Society 2014-2021

© Sevas Educational Society 2008

Abstract

This research deals with the organic extracts impact of *Bunium incrassatum* on the immune expression of estrogen receptors that is the assessment of the effect of organic extracts from the seeds of *Bunium incrassatum* (Apiaceae) on the immune labelling of estrogen receptors in the adrenal gland of pregnant rabbits from the local population (*Oryctolagus cuniculus*). The work was carried out on pregnant rabbits during the last third of gestation (from day 17 to day 27 of gestation). The animals were divided into four groups which received daily oral doses: 50, 100, and 200 mg/kg/day, respectively. The group with dose 0 was taken as a control. After treatment, the rabbits were sacrificed (28th day of gestation). Their organs were removed, defatted, and weighed then fixed in 10% formalin and the blood was collected in tubes with heparin. For immunohistochemistry, mouse monoclonal antibodies were used to determine the ER presence in the adrenal gland of rabbits. Therresults indicated that treatment with organic extract of *Bunium incrassatum* induced an increased rate of change in the thickness of the adrenal cortex in the treated groups compared to the control. A strong immune expression of estrogen receptors was observed in the groups treated with 50 and 100 mg / kg / day compared to the group treated with 200 mg/ kg/day. It can be concluded that estradiol has a direct effect on adrenal function in pregnant rabbits. Likewise, the components of the organic extract from the roots of *Bunium incrassatum* have modulatory activities for ER.

Naoual Hammoudi, Hind Djebaili

Laboratory of Biomolecules and Plant Breeding, University of Larbi Ben M'hidi, Oum El Bouaghi, Algeria.
National Center for Biotechnology Research, Constantine, Algeria.

Souad Boulahbel, Sana Chentouh, Yasmina Bentayeb*

Laboratory of Biomolecules and Plant Breeding, University of Larbi Ben M'hidi, Oum El Bouaghi, Algeria.

Amina Wissamehadjeris

Departement of Medicine, Faculty of Medicine, University of Constantine 03, Constantine, Algeria.

Nouredine Gherraf

Laboratory of Natural Resources and Management of Sensitive Environments, University of Larbi ben M'hidi, Oum El Bouaghi, Algeria.

*E-mail: yasmina.bentayeb@yahoo.com

Keywords: Pregnant rabbits, Adrenal gland, *Bunium incrassatum*, Estrogen receptors

Introduction

The adrenal glands are considered to be the most important endocrine glands due to their involvement in the main biological functions in animals (Hussein, 2015). They are composed of two embryologically distinct parts: the outer adrenal cortex and the inner adrenal medulla (St-Jean *et al.*, 2020). The adrenal cortex is made up of three areas of cells that synthesize, through multiple enzymatic steps, and different steroid hormones (Arlt & Stewart, 2005).

The structure of this gland depends on the species, age, sex, season, and condition of the organism including gestation (Sofia *et al.*, 2021). Pregnancy is a physiological condition that causes changes in the maternal body, such as adrenal hypertrophy. In rabbits, adrenal hypertrophy is confined to late gestation and the intermediate postpartum period (Dumontet *et al.*, 2018; Aboud *et al.*, 2019; Al-Shakhshir *et al.*, 2019). This structure is generally sensitive to external and internal factors such as phytoestrogens (Russel *et al.*, 2017). Phytoestrogens are food compounds of plant origin showing structural similarity to 17- β -estradiol (E2). This structural similarity allows them to directly interfere with steroid biosynthesis, intracellular signaling, cell proliferation, and gene expression (Toyohira *et al.*, 2010; Polluzi *et al.*, 2014).

Bayala *et al.* (2006) demonstrated that the administration of extracts 100, 200 mg.kg-1 of *Holarrhena floribunda* in oophorectomy rats induces an increase in the fresh weights of the adrenal glands and that the aqueous extract of the leaves of *Holarrhena floribunda* contains phytoestrogens which behave like partial agonists. Similarly, Hammoudi *et al.* (2020), found that the relative adrenal weights showed a statistically insignificant decrease ($p > 0.05$) in pregnant rabbits treated with the organic extract of *Bunium incrassatum* compared to the control.

B. incrassatum is a widely used medicinal plant in eastern Algeria, especially in the region of Oum El Bouaghi, which belongs to the Apiaceae family. According to traditional healers in this region, it is used to increase the weight and milk secretion of some farm animals. The study of the chemical composition of seeds of *B. incrassatum* revealed the presence of coumarins scopoletin, Beta-Sitosterol, sucrose, and oleic acid (Bousetla *et al.*, 2015).



Previous phytochemical studies of this species have shown that its essential oil involves more than 45 compounds (Bousetla *et al.*, 2014). Our objective is to endure the work undertaken in our laboratory on the impact of the organic extracts of this plant on the immune expression of estrogen receptors.

Materials and Methods

Biological Material

The roots of *Bunium incrassatum* roots were grabbed in September 2015 from Bir Rogaa Oum El Bouaghi region. The identification of the plant was carried out in the "Laboratory of Plant Biomolecules and Plant Breeding" by a botanist. The roots were separated from the aerial parts of the plant, then well cleaned with water, cut and dried at room temperature in the shade, and protected from dust for a few days before being crushed into a fine powder using a mortar.

The extraction was carried out according to the protocol of reference (Bousetla *et al.*, 2015). One hundred grams (100g) of powder were macerated in 100 ml of ethanol and 100 ml of chloroform for 24 hours in the shade. The whole mixture was then filtered on Whatman paper (3 MM). The solvent was recovered by evaporation and about 3 ml of a brown liquid was obtained serving as the crude organic extract of *B. incrassatum*. This liquid is then diluted in distilled water to prepare the doses.

Animal Material

For this study, 24 multiparous pregnant rabbits of the local breed (*Oryctolagus cuniculus*), weighing between 2.66 and 3.66 Kg, were used.

Experimental Protocol

The experimental protocol is carried out in the autumn in the animal facility of the Hamma Bouziane Constantine Technical Institute for Breeding under natural conditions (temperature, photoperiod, and humidity). The rabbits were fed daily with a forage, in the form of pellets, supplied by the National Cattle Feed Board (O.N.A.B.) and were given water "ad libitum".

The first step is to put the does in the cages of the males for mating. After 12 days of mating, delicate palpation of the abdomen of the doe is done to confirm gestation. The number of 24 pregnant rabbits were divided into 4 groups of 6. The doses of the organic extract are diluted in distilled water and administered daily by gavage. Group 1 serving as the control also receives distilled water to remain under the same experimental conditions, and groups 2, 3, and 4, respectively receive doses of 50, 100, 200 mg/kg/day.

Sacrifice and Blood Collection

The treatment lasted for 10 days from the 17th day to the 27th day of gestation, the rabbits were sacrificed the day after the last gavage, the blood samples were taken from all the treated and control animals. Blood was collected in polyethylene tubes contain in heparin. The samples were taken, immediately after slaughter,

at the Ibn Sina laboratory in Constantine to carry out an analysis of hormonal parameters.

Parameters of Gland Weight

After the animal is sacrificed, the adrenal glands are defatted and weighed. They were fixed in 10% Formol for histological and immune histochemical studies. The relative weights of the glands were determined by the following formula.

$$\text{Relative organ weight} = \frac{\text{Absolute organ weight (g)} \times 100}{\text{Bodyweight of animal on the day of sacrifice (g)}} \quad (1)$$

Immunohistochemistry Protocol

Deparaffinization and Hydration

Put the sections in an oven at 37 ° overnight
Two xylene baths of 10 min
Two 10-minute 100 ° and 90 ° alcohol baths
Two one-minute 70 ° and 50 ° alcohol baths
Rinse with distilled water 5 min

Unmasking

Prepare a 1/10 dilution with DAKO Cytomation Target Retrieval Solution Citrate Ph6
Place in the water bath at 92-98 °
Put the blades 40-45 min
Cool the slides with water
Rinse 2-3 times with TBS

From this stage, the technique is carried out in a humid environment (on a plate with humidified gases below). The sample is circled using a Dako Pen; hydrophobic pencil to prevent runoff.

We used the NovocastraLeica kit

Blockage of Endogenous Peroxidases

Incubate the slides for 10 minutes with two drops of oxygenate (DAKO Peroxidase Blocking Reagent). Two TBS rinses (1/10) of 05 minutes

Protein Block

Incubate slides for 5 minutes with two drops of the Protein Blok solution. Two rinses with TBS diluted 1/10 for 05 minutes.

Application of the Primary Antibody

Incubate the slides for 30 minutes with the primary antibody (Dako) 100 µl 30min. Two rinses with TBS for 05 minutes.

Application of the Secondary Antibody

Incubate the slides for 30 minutes with the secondary antibody. Two rinses with TBS for 05 minutes.
Incubate the slides for 30 minutes with two drops of the polymer. Two rinses with TBS for 05 minutes.

The Revelation by Diaminobenzidine (DAB)

The secondary antibody is coupled to a peroxidase, which transforms DAB into a colored product with the following relationship:

Preparation of the DAB solution: 50µl DAB Chromogen + 1ml DAB Substrate Buffer

Incubate the slides for 03 minutes with 200 µl of the DAB solution.

Three rinses with TBS for 05 minutes

Counterstaining with hematoxylin

Montage aqueux: DakoGlycergel™ Mounting Medium (C0563)

The Statistical Study

The statistical evaluation in histology is carried out by the parametric test of Student and for oestradiol the nonparametric test Mann Whitney was used, using software XLSTAT, version 2014 and Excel 2015.

Microscopic Photograph

The photomicrographs were performed with an optical microscope (B-150 OPTIKA) equipped with a digital camera. The thickness of the histological layers of the adrenal gland was measured using Image J Fuji software from micrographs under a 10x objective of the control and processed adrenal gland sections. Eight measurements were taken around each adrenal section first for total cortical thickness and then for each zone thickness. The measurements were averaged for each group. Immunohistochemical reading was also performed using Image J Fuji software with the IHC Profiler option.

Results and Discussion

The results obtained on the effects of the organic extract of *B. incrassatum* in pregnant rabbits from the local population will focus on the histomorphometric parameters of the adrenal cortex areas, estradiol levels, and the immune expression of estrogen receptors in the adrenal cortex.

Results of the Histomorphometric Study of the Cortical Areas

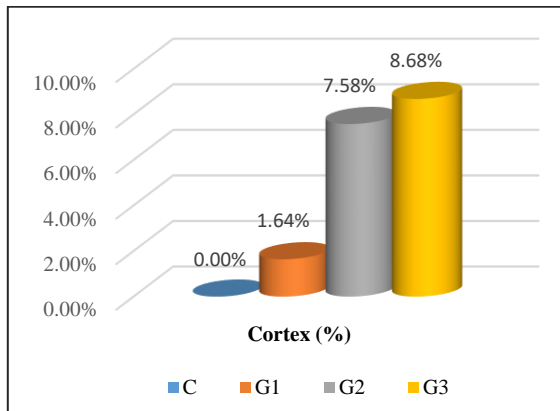


Figure 1. Rate of Change in Adrenal Cortex Thickness in Experimental Animals

An increase is observed in the rate of change in the thickness of the cortical zone of the treated rabbits compared to the control group.

This increase is in the order of 1.64%, 7.88%, and 8.68% in the animals treated with 50, 100, and 200 mg/kg / day, respectively (**Figure 1**).

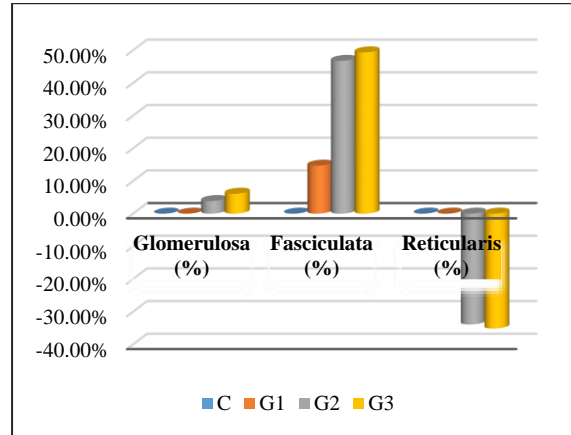


Figure 2. Rate of Change in Cortical Layer Thickness in Experimental Animals

The thickness of the glomerulosa area increased by 3.87% and 6.09% in the G2 and G3 groups, respectively, compared to that of the control and G1 groups. The thickness of the fasciculata area also increased with all doses of 50, 100, and 200 mg/kg / day with 14.69%, 46.75%, and 49.34%, respectively. In contrast, the thickness of the reticularis zone decreased by 33.90% and 31.10% in groups G2 and G3 compared to the control group and G1 (**Figure 2**).

Estradiol Results

The organic extract from the roots of *B. incrassatum* has no significant effect on the level of estradiol. The percentage change increased in the order of 25.80% in the group treated with 50 mg/kg/day and a decrease in the order of 2.20% and 27.24% in the groups treated with 100 and 200mg/kg/day, respectively, compared to the control group (**Figure 3**).

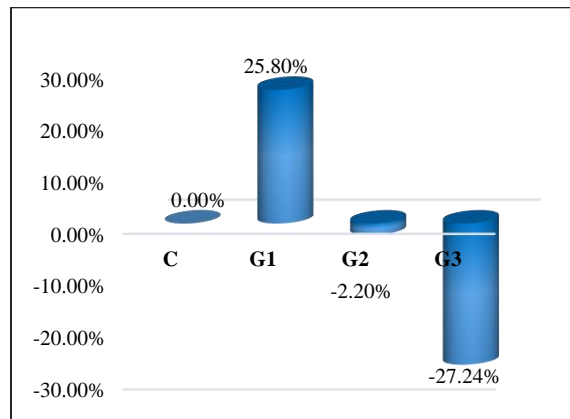


Figure 3. Rate of Change in Estradiol in Experimental Animals

Immunolocalization of ERs in the Adrenal Gland

In our study, we have localized by immunohistochemistry of the estrogen receptors in the three layers of the cortical and medullary zone of the adrenals of pregnant rabbits (**Figure 4**).

In addition, a statistical analysis in the present study revealed a very significant decrease in the percentage of positive immune response zone in the adrenal glands of pregnant rabbits treated with organic extract of *B. incrasatum* (**Tables 2 and 3**).

Marking Intensity

Table 1. IHC DAB Concentration in Each Area of the Adrenal Gland

	control	G1	G2	G3
Glomerulus	++	++	+	+
Fasciculated	+	+	+	0
Reticle	++	+++	++	0
Medulla	++	+++	++	+

High positive (3+), positive (2+), low positive (1+), negative (0+)

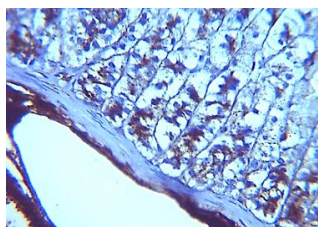
Marking Surface

Table 2. The Percentage of the Area Stained by IHC DAB (x10 image) of the Cortex


	control	G1	G2	G3
--	---------	----	----	----



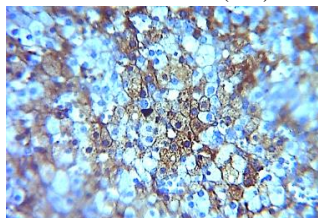
Adrenal Gland Control (x10)
Image a



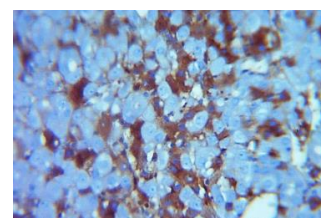
Glomerulus Area (x40)



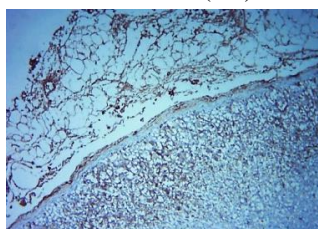
Fasciculated Area (x40)



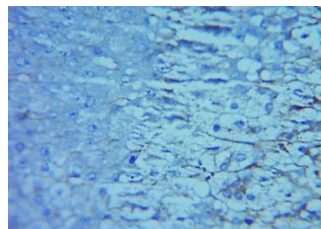
Reticle Area (x40)



Medulla (x40)



Glomerulus Area (x40)



Fasciculated Area (x40)

	control	G1	G2	G3
Cortex	18.51%	23.64%	3.16%	0.06%

Table 3. The Percentage of Area Stained by IHC DAB (x40 image) in Each Area of the Adrenal Gland

	control	G1	G2	G3
Glomerulus	14.80%	22.99%	16.73%	27.50%
Fasciculated	3.74%	9.19%	14.01%	0.66%
Reticle	51.92%	42.96%	58.22%	5.30%
Medulla	40.89%	70.28%	78.01%	3.37%

Estrogen receptor immuno histochemical staining was performed to detect the distribution of the estrogen receptor in the adrenal gland of the four groups. The immuno-positive reaction appeared as dark brown dots. The control group showed a slightly positive brown staining with a uniform distribution of activity in both the cortex and the medullary zone (Image a). In the adrenal glands of pregnant rabbits treated with the organic extract of *B. incrasatum* by the dose 50 and 100, the brownish discoloration was increased compared to the control, indicating increased estradiol activity in the adrenal cortex (Images b & c) while in the adrenal glands of the 200-treated group the brownish discoloration was decreased (Image d).

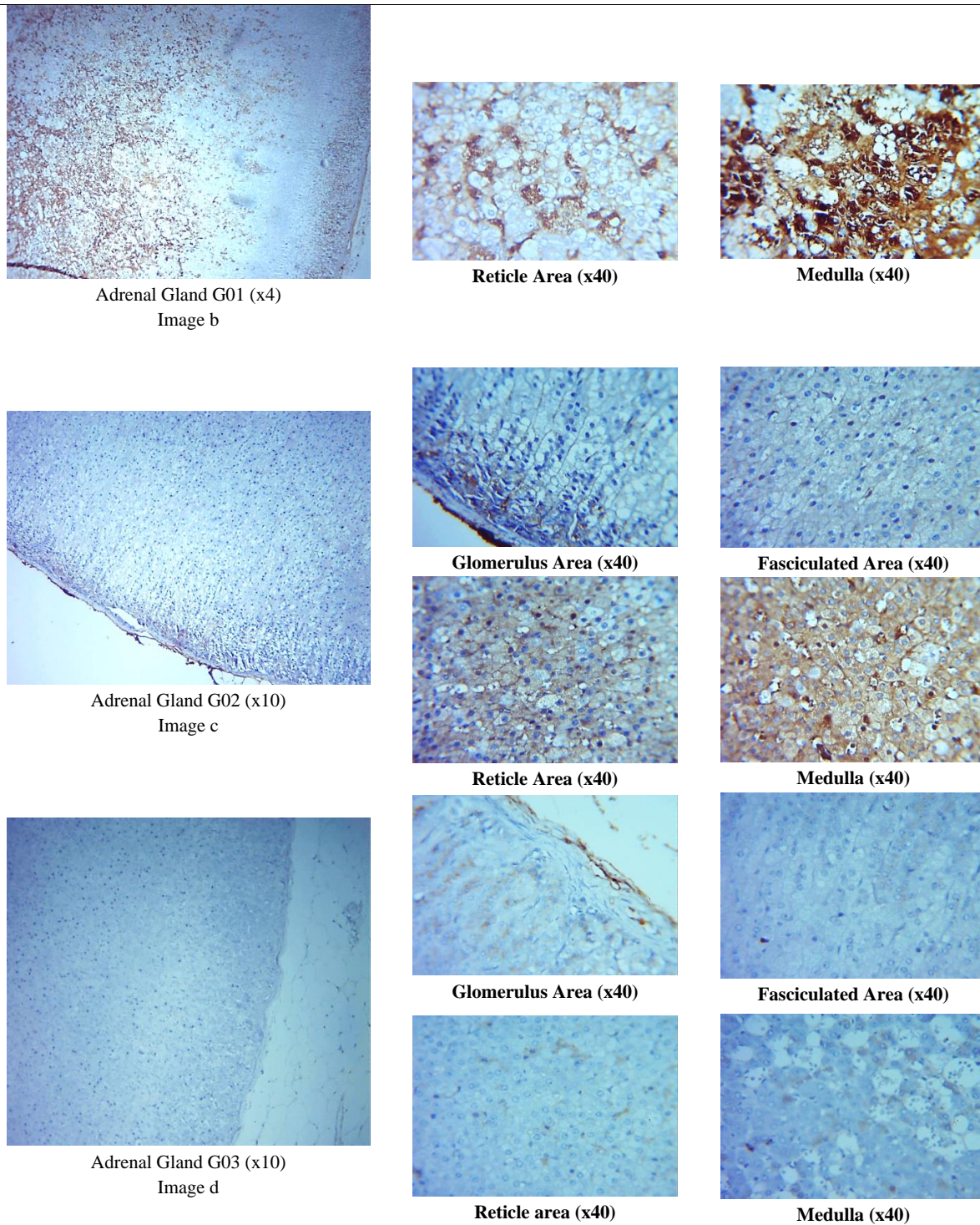


Figure 4. Immunolocalization of ERs in the Adrenal Gland

The objective of this work is to evaluate the effect of treatment of pregnant rabbits with the organic extract of *B. incrassatum* on the immuno expression of estrogen receptors in the adrenal gland. The animals were divided into 4 groups which received daily doses of 50, 100, 200 mg/kg/day. The group with dose 0 was taken as a control. It is well known that adrenal cortex activity in mammals is sensitive to androgens and estrogen and undergoes minimal

changes in weight and size (Goel *et al.*, 2014; Trijter *et al.*, 2015; Gannon *et al.*, 2019).

Our results indicate an increased rate of change in the thickness of the cortical zone of the treated rabbits compared to the control group. This increase is in the order of 1.64%, 7.88%, and 8.68% in animals treated with 50, 100, and 200 mg/kg/day, respectively. We also noticed that the thickness of ZG increased by 3.87% and

6.09% in the G1 and G2 groups, respectively, compared to that of the control group.

ZF thickness increased by 14.69%, 46.75%, and 49.43% in groups G1, G2, and G3, respectively. In contrast, the thickness of ZR decreased by 33.90%, 31.10% in the G2 and G3 groups compared to the control and G1 group. These results agree with those of Zatra (Zatra, 2008), who found in *Gerbilus*, clear hypertrophy of the cortex mainly due to the fascicular area. These morphometric changes can be explained by the presence of β -Sitosterol in the extract of this plant.

This component belongs to the family of plant sterols or Phytosterols (Brown *et al.*, 2014). It is well documented that phytoestrogens are naturally occurring chemicals that can directly interfere with steroid biosynthesis, intracellular signaling, cell proliferation, and gene expression (Giraldi *et al.*, 2010; Lecomte *et al.*, 2017). Many studies (Rosol *et al.* 2001; Miller *et al.*, 2021; Pignatti & Flück, 2021) reported that exogenous steroids can disrupt the function and normal structure of the adrenal cortex.

Rosol *et al.* (2001) have observed that exogenous agonists induce negative feedback inhibition of ACTH secretion by the pituitary gland and lead to atrophy of the Fasciculated and reticular zone, while exogenous steroid antagonists block the action of steroid hormones, causing an increased secretion of ACTH and a cortex hyperplasia diffusion.

In our study, we showed that the absence of the significant effect of the organic extract of the roots of *B. incrassatum* on the estradiol level is due to the presence of β -Sitosterol and that the rate of change experienced an increase of around 25.80% in the group treated with 50 mg/kg/day and a decrease of around 2.20% and 27.24% in the groups treated with 100 and 200 mg/kg/day, respectively, in comparison with the control group.

Several studies showed that treatment with β -Sitosterol induces a decrease in circulating steroids (Moghadasian, 2000). Maclatchy and Vanderkraak (1995) reported that intraperitoneal injections of β -Sitosterol significantly reduced testosterone and 11 - ketotestosterone in males and levels of testosterone and 17 β -estradiol in female goldfish. They also reported that pregnenolone levels were significantly reduced compared to beta-Sitosterol.

The same researchers showed that fish exposed to β -Sitosterol showed a decrease in circulating steroid levels. This drop is due to the inhibition of the enzyme P450 aromatase by the scopoletin found in the extract. This inhibitory action is enhanced by β -Sitosterol (Balunas *et al.*, 2008).

The aromatization of androgens into estrogen is mediated by this key enzyme, located in the endoplasmic reticulum in various tissues, including the adrenal cortex (Conley *et al.*, 1996). Besides, Meemak *et al.*, (2016) and Lecompte *et al.*, (2017) showed that phytoestrogens, when given in high doses, can cause hormonal imbalance that can even compete with estrogen and behave like antiestrogens.

We noticed that the reduction recorded in our results is not significant. We can explain this by the presence of β -caryophyllene (BCP) in the organic extract of this plant which corrected the negative effect of β -Sitosterol on steroid secretion. According to studies by Fiorenzani *et al.* (2014), the administration of BCP alone increases the level of testosterone and estradiol. These hormones can affect the growth and function of the adrenal cortex, either via central pathways (hypothalamic CRH and Adeno hypophyseal ACTH) or directly, with great probability, via specific receptors expressed in the cortex and/or by interfering with adrenal cortex enzymes including those involved in steroidogenesis (Kling, 2016).

The results of the immuno histochemical study of the adrenal gland of pregnant rabbits treated with the organic extract of *B. incrassatum* and control, allowed us to collect data usable in research to demonstrate the immuno localization and the intensity of labeling of biomarkers in different parts of a tissue such as estrogen receptors (**Table 1**). 17 β -Estradiol, as the main circulating estrogen hormone, regulates many tissue and organ functions in physiology. Estrogens exhibit various effects throughout the body by binding to one of the two variants of estrogen receptor (ER) α and ER β that are encoded by distinct genes (Van Pelt *et al.*, 2015; Yasar *et al.*, 2016) and which are members of the nuclear receptor superfamily of transcription factors (Hua *et al.*, 2018). The identification of these receptors in mammals was made by Kuiper *et al.* (1996).

Our results showed that estrogen receptor expression was detected in fat cells, connective tissue fibroblast cells as well as cells of the glomerular, fascicular, and reticular layer and the medullary area.

The results of this study are consistent with those carried out on other species. For example, ER staining has been found in all areas of the adrenal cortex in rhesus monkeys (Goel *et al.*, 2014) and sheep (ER α) (Henley & Korach, 2010). Likewise, since molecular studies became available, ER has been identified in adrenal tissue in several species such as rodents and primates (Calandra *et al.*, 1980).

The presence of ERs was detected by a brown stain (positive immune stain) in different parts of the adrenal gland with varying intensity. The adrenal glands of the rabbits treated with the 200 mg/kg/day dose showed a lower intensity of ER staining (weak) compared to the other groups treated with 50 and 100 mg/kg/day and control (**Table 1**).

However, rabbits treated with the 100 mg/kg/day dose showed stronger ER staining in the adrenal cortex than the other groups. The variability in estrogen receptor expression observed in our results is due to different components of *B. incrassatum* such as β -Sitosterol, sucrose, and oleic acid. We can explain this drop in ER concentration in rabbits by the decrease in estradiol levels. It is well recognized that there is an inverse relationship between the abundance of sex steroid receptors and circulating hormone levels (Watts, 2020).

This was proved by Van Lier *et al.* (2003) who demonstrated that gonadectomy in both sexes of sheep increased adrenal ER observed in comparison with their intact counterparts, confirming that the regulation of the adrenal gland is under the control of sex steroids. Gaya *et al.* (2018) have proven by studies on small animals that the consumption of sucrose is sufficient to induce metabolic changes in the body which lead to deleterious consequences and induce a significant decrease in the expression of ER α .

Conclusion

Our results show the presence of estrogen receptors in the adrenal cortex, indicating that estradiol has a direct effect on adrenal function in pregnant rabbits. Likewise, the components of the organic extract from the roots of *Bunium incrassatum* have modulatory activities for estrogen receptors.

Acknowledgments: We would like to express our gratitude to Khalfaoui Zakaria, director of technical institute of breeding, Hamma Bouziane Constantine, for his exceptional involvement.

Conflict of interest: None

Financial support: None

Ethics statement: Animal ethics approval was obtained from Animal Care Committee of the National Biotechnology Research Center in Algeria and was in accordance with guidelines of the International Bioethics Committee, European Institute of Bioethics and World Organization of Animal Health.

References

- Aboud, S. A. E. H., El Sayed, H. A. E., & Ibrahim, H. A. F. (2019). Knowledge, Attitude and Practice Regarding Prevention of Iron Deficiency Anemia among Pregnant Women in Tabuk Region. *International Journal of Pharmaceutical Research & Allied Sciences*, 8(2), 87-97.
- AL-Shakhshir, S. M., Sulaiman, S. A. S., Alhaddad, M. S., & Ismail, M. P. (2019). Assessment of the Effectiveness of a Pharmacist-Led Digital Educational Program on Knowledge, Perception, and Practice of Pregnant Women at a Tertiary Care Teaching Hospital. *Archives of Pharmacy Practice*, 10(1), 5-11.
- Arlt, W., & Stewart, P. M. (2005). Adrenal corticosteroid biosynthesis, metabolism, and action. *Endocrinology and Metabolism Clinics*, 34(2), 293-313. <https://pubmed.ncbi.nlm.nih.gov/15850843/>
- Balunas, M. J., Su, B., Brueggemeier, R. W., & Kinghorn, A. D. (2008). Natural products as aromatase inhibitors. *Anti-Cancer Agents in Medicinal Chemistry (Formerly Current Medicinal Chemistry-Anti-Cancer Agents)*, 8(6), 646-682. <https://www.ncbi.nlm.nih.gov/pmc/articles/PMC3074486/>
- Bayala, B., Tamboura, H. H., Pellicer, M. T. R., Zongo, D., Traoré, A., Ouédraogo, L & Sawadogo, L. (2006). Effets œstrogéniques du macéré aqueux des feuilles de *Holarrhena floribunda* (G. Don) Dur & Schinz chez la rate ovariectomisée. *BASE*, 10(3), 173-180. <https://popups.uliege.be/1780-4507/index.php?id=997>
- Boussetla, A., Kurkcuoglu, M., Konuklugil, B., Baser, K. H. C., & Rhouati, S. (2014). Composition of Essential Oil from *Bunium incrassatum* from Algeria. *Chemistry of Natural Compounds*, 50(4), 753-755. <https://link.springer.com/article/10.1007/s10600-014-1074-x>
- Boussetla, A., Zellagui, A., Derouiche, K., & Rhouati, S. (2015). Chemical constituents of the roots of Algerian *Bunium incrassatum* and evaluation of its antimicrobial activity. *Arabian Journal of Chemistry*, 8(3), 313-316. <https://www.sciencedirect.com/science/article/pii/S1878535211000268>
- Brown, A. C., Stevenson, L. M., Leonard, H. M., Nieves-Puigdoller, K., & Clotfelter, E. D. (2014). Phytoestrogens β -sitosterol and genistein have limited effects on reproductive endpoints in a female fish, *Betta splendens*. *BioMed Research International*, 2014. Article ID 681396, 7 pages. doi:10.1155/2014/681396, <https://www.hindawi.com/journals/bmri/2014/681396/>
- Calandra, R. S., Lüthy, I., Finocchiaro, L., & Cheb Terrab, R. (1980). Influence of sex and gonadectomy on sex steroid receptors in rat adrenal gland. *Journal of Steroid Biochemistry*, 13(11), 1331-1335. <https://www.sciencedirect.com/science/article/abs/pii/0022473180900941>
- Conley, A. J., Corbin, C. J., Hinshelwood, M. M., Liu, Z., Simpson, E. R., Ford, J. J., & Harada, N. (1996). Functional aromatase expression in porcine adrenal gland and testis. *Biology of Reproduction*, 54(2), 497-505. <https://academic.oup.com/biolreprod/article/54/2/497/2761972>
- Dumontet, T., Sahut-Barnola, I., Septier, A., Montanier, N., Plotton, I., Roucher-Boulez, F., Ducros, V., Lefrançois-Martinez, A. M., Pointud, J. C., Zubair, M., et al. (2018). PKA signaling drives reticularis differentiation and sexually dimorphic adrenal cortex renewal. *JCI Insight*, 3(2), e98394. doi:10.1172/jci.insight.98394
- Fiorenzani, P., Lamponi, S., Magnani, A., Ceccarelli, I., & Aloisi, A. M. (2014). In vitro and in vivo characterization of the new analgesic combination beta-caryophyllene and docosahexaenoic acid. *Evidence-Based Complementary and Alternative Medicine*, 2014. doi:10.1155/2014/596312, <https://pubmed.ncbi.nlm.nih.gov/25097659/>
- Gannon, A. L., O'hara, L., Mason, J. I., Jørgensen, A., Frederiksen, H., Milne, L., Smith, S., Mitchell, R. T., & Smith, L. B. (2019). Androgen receptor signalling in the male adrenal facilitates X-zone regression, cell turnover and protects against adrenal degeneration during ageing. *Scientific Reports*, 9(1), 1-16. doi:10.1038/s41598-019-46049-3
- Gaya, P., Sánchez-Jiménez, A., Peirotn, Á., Medina, M., & Landete, J. M. (2018). Incomplete metabolism of phytoestrogens by gut microbiota from children under the age of three. *International Journal of Food Sciences and Nutrition*, 69(3), 334-343. <https://pubmed.ncbi.nlm.nih.gov/28728453/>

- Giraldi, T., Giovannelli, P., Di Donato, M., Castoria, G., Migliaccio, A., & Auricchio, F. (2010). Steroid signaling activation and intracellular localization of sex steroid receptors. *Journal of Cell Communication and Signaling*, 4(4), 161-172. <https://pubmed.ncbi.nlm.nih.gov/21234121/>
- Goel, N., Workman, J. L., Lee, T. T., Innala, L., & Viau, V. (2014). Sex differences in the HPA axis. *Comprehensive Physiology*, 4(3), 1121-1155. <https://pubmed.ncbi.nlm.nih.gov/24944032>
- Hammoudi, N., Hafid, H., Moumen, Y., Chentouh, S., Djebaili H., & Boulahbel S. (2020). Effect of organic materials extract from *Buniumincrassatum* (Talgouda) roots on hematological and histological parameters of the adrenal glands in the pregnant rabbits, *Oryctolagus cuniculus*. *Journal of New Technology and Materials*, 10(1), 38-43. <https://www.asjp.cerist.dz/en/article/117323>
- Henley, D. V., & Korach, K. S. (2010). Physiological effects and mechanisms of action of endocrine disrupting chemicals that alter estrogen signaling. *Hormones*, 9(3), 191-205. <https://www.ncbi.nlm.nih.gov/pmc/articles/PMC4782146/>
- Hua, H., Zhang, H., Kong, Q., & Jiang, Y. (2018). Mechanisms for estrogen receptor expression in human cancer. *Experimental Hematology & Oncology*, 7(1), 24. doi:10.1186/s40164-018-0116-7
- Hussein, A. A. (2015). Histomorphological developmental study of the adrenal gland of the local rabbit at one- and fifteen-day's age. *Al-Qadisiyah Journal of Veterinary Medicine Sciences*, 14(2), 47-54. <https://www.iasj.net/iasj/article/109541>
- Klinge, C. M. (2016). Part III: Steroid Hormone Receptors and Signal Transduction Processes. In: Belfiore A., LeRoith D. (eds) *Principles of Endocrinology and Hormone Action*. Endocrinology. Springer, Cham. pp 1-47. doi:10.1007/978-3-319-27318-1_9-1
- Kuiper, G. G., Enmark, E., Peltö-Huikko, M., Nilsson, S., & Gustafsson, J. A. (1996). Cloning of a novel receptor expressed in rat prostate and ovary. *Proceedings of the National Academy of Sciences*, 93(12), 5925-5930. <https://www.ncbi.nlm.nih.gov/pmc/articles/PMC39164/>
- Lecomte, S., Demay, F., Ferrière, F., & Pakdel, F. (2017). Phytochemicals Targeting Estrogen Receptors: Beneficial Rather Than Adverse Effects?. *International Journal of Molecular Sciences*, 18(7), 1381. doi:10.3390/ijms18071381
- Maclatchy, D. L. & Vanderkraak, G. J. (1995). The phytoestrogen β -sitosterol alters the reproductive endocrine status of goldfish. *Toxicology and Applied Pharmacology*, 134(2), 305-312. <https://www.sciencedirect.com/science/article/abs/pii/S0041008X85711969>
- Meemak, T., Daduang, J., & Boonsiri, P. (2016). Equol: a Phytoestrogen from Soy Bean: Its Roles in Health. *Ramathibodi Medical Journal*, 39(2), 132-141. <https://he02.tci-thaijo.org/index.php/ramajournal/article/view/57629>
- Miller, W. L., Flück, C. E., Breault, D. T., & Feldman, B. J. (2021). The adrenal cortex and its disorders. *Sperling Pediatric Endocrinology* (Fifth Edition). Pages 425-490. doi:10.1016/B978-0-323-62520-3.00014-2
- Moghadasian, M. H. (2000). Pharmacological properties of plant sterols: in vivo and in vitro observations. *Life Sciences*, 67(6), 605-615. <https://pubmed.ncbi.nlm.nih.gov/12659166/>
- Pereira, S. S., Carvalho, L., Costa, M. M., Melo, A., Ferreira, I. M., Gomez-Sanchez, C. E., Monteiro, M. P., Vinson, G. & Pignatelli, D. (2021). Mineralocorticoid Receptor Antagonists Eplerenone and Spironolactone Modify Adrenal Cortex Morphology and Physiology. *Biomedicines*, 9(4), 441. doi:10.3390/biomedicines9040441
- Pignatti, E., & Flück, C. E. (2021). Adrenal cortex development and related disorders leading to adrenal insufficiency. *Molecular and Cellular Endocrinology*, 527, 111206. doi:10.1016/j.mce.2021.111206
- Poluzzi, E., Piccinni, C., Raschi, E., Rampa, A., Recanatini, M. & De Ponti, F. (2014). Phytoestrogens in postmenopause: the state of the art from a chemical, pharmacological and regulatory perspective. *Current Medicinal Chemistry*, 21(4), 417-436. doi:10.2174/09298673113206660297
- Rosol, T. J., Yarrington, J. T., Latendresse, J & Capen, C. C. (2001). Adrenal gland: structure, function, and mechanisms of toxicity. *Toxicologic Pathology*, 29(1), 41-48. <https://pascal-francis.inist.fr/vibad/index.php?action=getRecordDetail&idt=971099>
- Russell, A. L., Grimes, J. M., Larco, D. O., Cruthirds, D. F., Westerfield, J., Wooten, L., Keil, M., Weiser, M. J., Landauer, M. R., Handa, R. J., et al. (2017). The interaction of dietary isoflavones and estradiol replacement on behavior and brain-derived neurotrophic factor in the ovariectomized rat. *Neuroscience Letters*, 640, 53-59. doi:10.1016/j.neulet.2017.01.011
- St-Jean, M., Bourdeau, I., & Lacroix, A. (2020). Adrenal Cortex and Medulla Physiology during Pregnancy, Labor, and Puerperium. In *Maternal-Fetal and Neonatal Endocrinology*. Academic Press. 101-116 <https://www.sciencedirect.com/science/article/pii/B9780128148235000088>
- Toyohira, Y., Ueno, S., Tsutsui, M., Itoh, H., Sakai, N., Saito, N., Takahashi, K. & Yanagihara, N. (2010). Stimulatory effects of the soy phytoestrogen genistein on noradrenaline transporter and serotonin transporter activity. *Molecular Nutrition & Food Research*, 54(4), 516-524. <https://pubmed.ncbi.nlm.nih.gov/20087855/>
- Trejter, M., Jopek, K., Celichowski, P., Tyczewska, M., Malendowicz, L. K., & Rucinski, M. (2015). Expression of estrogen, estrogen related and androgen receptors in adrenal cortex of intact adult male and female rats. *Folia Histochemica et Cytobiologica*, 53(2), 133-144. doi:10.5603/FHC.a2015.0012
- Van Lier, E., Meikle, A., Bielli, A., Åkerberg, S., Forsberg, M., & Sahlin, L. (2003). Sex differences in oestrogen receptor levels in adrenal glands of sheep during the breeding season. *Domestic Animal Endocrinology*, 25(4), 373-387. <https://pubmed.ncbi.nlm.nih.gov/14652137/>
- Van Pelt, R. E., Gavin, K. M., & Kohrt, W. M. (2015). Regulation of Body Composition and Bioenergetics by Estrogens. *Endocrinology and metabolism clinics of North America*, 44(3), 663-676. doi:10.1016/j.ecl.2015.05.011

-
- Watts, H. E. (2020). Seasonal regulation of behaviour: what role do hormone receptors play? *Proceedings. Biological Sciences*, 287(1930), 20200722. doi:10.1098/rspb.2020.0722
- Yaşar, P., Ayaz, G., User, S. D., Güpür, G., & Muyan, M. (2016). Molecular mechanism of estrogen-estrogen receptor signaling. *Reproductive Medicine and Biology*, 16(1), 4-20. doi:10.1002/rmb2.12006
- Zatra, Y. (2008). *Influence de la castration en période de reproduction sur l'activité du cortex surrénal chez la gerbille mâle* (Doctoral dissertation), usthb, Alger Algérie. <https://repository.usthb.dz/handle/123456789/3018>