

Hepato-Renal Protection of Methanol Flavonoid-Fraction of Lime Juice in Rats Fed Monosodium Glutamate and Protein-Enriched Diet

Idoko Alexander*, Parker Joshua Elijah, Njoku Obioma Uzoma, Ezeh Ernest Mbamalu, Ndubuisi Jennifer Chioma, Nwali Nelson Onubuiwe

Received: 30 August 2024 / Received in revised form: 03 December 2024, Accepted: 05 December 2024, Published online: 19 December 2024

Abstract

Flavonoid-rich plant compounds are known for their beneficial multi-health functions. The liver and kidney protective potentials of fresh lime juice (FLJ), 50% FLJ and 50% honey combination (MIX), and the methanol flavonoid-rich fraction of lime juice (MFLJ) were examined in this study. Three sets of eighteen male neonatal Wistar rats (phase I) were utilized, totaling fifty-four. Rats in group III were given a diet rich in protein for 14 days, and those with a Lee index of 0.3 or higher were classified as obese. In group II, obesity was created by intraperitoneal injection of 5 mg/kg body weight of monosodium glutamate (MSG). Rats were rearranged into seven groups of six (phase II), and FLJ, MIX, and MFLJ were administered. Characterizing the flavonoids in MFLJ involved the use of high-performance liquid chromatography (HPLC). Gallic acid, caffeic acid, p-coumaric acid, sinapic acid, and quercetin—all of which provide hepato-renal protection—were discovered in MFLJ during HPLC analysis. Comparing obese rats to control and AOI rats, the body weight, food intake, adiposity index, and weight of liver, kidney, and heart all decreased considerably ($p < 0.05$) following FLJ, MIX, and MFLJ therapy. When compared to AOI and control rats, FLJ, MIX, and MFLJ therapy significantly ($p < 0.05$) improved the liver, and kidneys functions, and restored normal architecture of adipose, and hepatic tissues in obese treated rats. Obviously, these flavonoids in MFLJ could serve as model pharmacotherapy for the treatment and management of hepatic and renal dysfunction in obesity.

Keywords: Antioxidant, Flavonoids, Obesity, Hepatoprotective, Vitamin C

Introduction

The liver is a very vital organ of metabolic and detoxifying interest. It is essentially involved in the metabolism of fats and glucose and

Idoko Alexander*, Ndubuisi Jennifer Chioma, Nwali Nelson Onubuiwe

Department of Biochemistry, Faculty of Natural Sciences, Caritas University, Amorji-Nike, Enugu, Nigeria.

Parker Joshua Elijah, Njoku Obioma Uzoma

Department of Biochemistry, Faculty of Biological Sciences, University of Nigeria, Nsukka, Nigeria.

Ezeh Ernest Mbamalu

Department of Chemical Engineering, Faculty of Engineering, Federal University, Otuoke, Bayelsa, Nigeria.

*E-mail: alexidoko@caritasuni.edu.ng

the detoxification of xenobiotics. Thus, hepatic malfunction is often associated with metabolic complications such as diabetes, obesity, hyperlipidemia, hyperglycemia, hypertension, and insulin resistance (Tran *et al.*, 2023). In an obese state, fatty liver disease onset is non-negotiable, due to the high influx of fats and their accumulation in the liver, resulting in metabolic dysfunction-associated fatty liver disease (Eleazu *et al.*, 2022). The liver enzymes such as alanine aminotransferase and aspartate aminotransferase are released in blood circulation due to hepatic injury (Thuy *et al.*, 2023). Therefore, it is essential to assay the blood activities/concentrations of liver function markers such as ALT, AST, ALP, TP, Abumin, T-Bil, and D-Bil in order to ascertain the liver's functional condition (Zakaria *et al.*, 2021). Renal illness and hepatic impairment have been linked to obesity, according to reports (Ezeigwe *et al.*, 2020; Yilmaz *et al.*, 2023). The kidney function is estimated from metabolic waste products, creatinine, and urea (Rock *et al.*, 1987). The amount of creatinine in the blood indicates a balance of its synthesis and removal by the renal system (Idoko *et al.*, 2020). The cellular cytoplasmic release of ALT is directly associated with the liver's condition of health and function (Ezeigwe *et al.*, 2022).

Flavonoids are known to exert their pharmacological effects due to their antioxidant capacity (Bich *et al.*, 2023; Kumbhar *et al.*, 2024). Flavonoids exhibit their antioxidant properties through their ability to scavenge free radical molecules, including reactive oxygen species (ROS) and reactive nitrogen species (RNS) (Okafor *et al.*, 2022). Free radicals are capable of preventing biochemical processes through enzyme inhibition. However, their elimination by flavonoids' antioxidant activity could confer protection on tissues and cells (Okafor *et al.*, 2022; Shahidi & Hossain, 2023; Singar, 2024).

Several health benefits are associated with flavonoids; Catechin inhibits plasma oxidation in humans (Idoko, 2019) compared with other antioxidants (Grzesik *et al.*, 2018); gallic acid exerts an anti-obesity effect and enhances learning in high-fat diet obese rats (Chen *et al.*, 2023); quercetin possesses anti-diabetic and anti-obesity effects in rats, epigallocatechin exhibited anti-obesity and cardiovascular protection on rats and hypoglycemic, anti-inflammatory, hypolipidemic and anticancer properties of caffeic acid are reported (Okafor *et al.*, 2022). These flavonoids were reported to be the most significant antioxidant compounds, coordinating antioxidant activity in Southern grape seeds (Darwish *et al.*, 2023). The hepato-renal protective properties of an ethylacetate flavonoid-rich honey fraction (EAFH) and a methanol flavonoid-rich fraction of fresh lime juice (MFLJ) were examined in the present research.



Materials and Methods

Collection of Citrus Fruit

Fresh lime fruit was harvested in the Nigerian state of Enugu from an orchard in the Imezi-Owa neighborhood of the Ezeagu Local Government Area. Lime fruits were identified and confirmed by Mr. Onyeukwu John Chijioke of the Department of Plant Sciences at the University of Nigeria Nsukka in Enugu State, using the University of Nigeria Herbarium (UNH number) 622a voucher (authentication number).

Collection of Honey

Fresh honey was harvested using a comb at Divine Favour Bee-keeping and Honey Production Farm in Ezikolo Abbi, Uzo-Uwani Local Government Area, Enugu State, Nigeria.

Preparation and Processing of Plant and Honey Samples

Freshly picked Citrus aurantifolia fruits were carefully cleaned, cut into two halves, and then gently squeezed. After filtering the

$$\text{Volume to be administered (ml)} = \frac{\text{Weight of rats (Kg)} \times \text{Dose (mg/Kg)}}{\text{Concentration of the extract (mg/ml)}} \quad (1)$$

Composition of Diet in g/1000 g

With a few minor adjustments, a diet mixture for an animal protein-enriched diet was created using Rotimi *et al.*'s methodology (Rotimi *et al.*, 2012).

Animal Protein-Rich Diet Mix Contains the Following in g/1000 g

Starter feed 218, chicken breast 197, pulverized milk 200, Egg white 36, Pork's flesh 82, and crayfish 267.

Fractionation of Bioactive Compounds from Fresh Lime Juice Using Different Extracting Solvents by Column Chromatographic Technique

The separation of concentrated lime juice's bioactive components was guided by qualitative phytochemical screening (Al-Rimawi *et al.*, 2018). In a silica gel column with a mesh size of 120–200, the extract (76.32 g) was subjected to solvent-guided fractionation. The extract was then progressively eluted with n-hexane, ethylacetate, dichloromethane, methanol, and 100% ethanol. A water bath was used to collect and concentrate the solvent fractions. Nevertheless, no phytochemical component could be eluted by dichloromethane or n-hexane. Three fractions are obtained from the concentrated solvent fractions: ethyl acetate, methanol, and ethanol. A screening guide for qualitative phytochemicals was used to filter the extract and its fractions. Based on the greatest flavonoid concentrations, the methanol fraction was shown to be the most active fraction. As a result, graded mixes of methanol and ethanol (1:0, 9:1, 8:2, 6:4, 4:6, 5:5) were used to elute the methanol fraction using a silica gel column with a mesh size ranging from 60 to 120. In 100-ml quantities, the sub-fractions were gathered. Temperature-controlled water baths holding the sub-fractions were used for concentration. The sub-

resultant lime juice, the remaining pulp and seeds were thrown away. To avoid fermentation, new lime juice was made whenever necessary. Five hundred (500) ml of the lime juice was concentrated in a water bath at 75°C for 48 hours to obtain a semi-solid residue, to be used for further analysis. The honeycomb was separated from the honey by a careful squeeze, and on blood agar, the honey purity was checked by inoculating and incubating overnight. Uncontaminated honey was stored at room temperature and made available for use when needed. In addition, other steps taken to check the purity and originality of the honey sample include; purity was ascertained when (i) as the honey dropped on sand, it did not sink immediately (ii) honey droplet on a finger dipped inside the honey sample went down without breaking in thread-like form and (iii) a little quantity dropped in a cup of water went to the bottom and did not mixed up with water until stirred (Olusolade & Akintayo, 2014).

The volume of extract to be supplied was estimated based on the rats' body weight using the formula:

fractions were subsequently subjected to a qualitative phytochemical screening activity guide to detect flavonoids.

High-Performance Liquid Chromatography (HPLC)

Exceptional performance in liquid chromatography the quantity and types of flavonoids in the methanol flavonoid-rich fraction of fresh lime juice (MFLJ) were investigated using a diode array (DA) detector and N200 chromatography software (Al-Rimawi *et al.*, 2018). An hour and thirty minutes were spent in a closed test tube after 0.1 g of the MFLJ sample was dissolved in 10 ml of 70% methanol. The extracted material was transferred into a 5 ml sample container, centrifuged, and then filtered through a micron filter. A tiny syringe was used for sample injection in the high-sensitivity LC-8518 diode array (DA) detector, which was equipped with a high-pressure switching valve, low-pressure gradient, and solvent supply LC-8518 pump while performing HPLC. 150 x 4.6 mm is the size of the column, and 40 µL of sample was utilized. Using a 25:74:1 acetonitrile/water/formic acid combination as the mobile phase, the system ran for 25 minutes at a temperature of 400 degrees Celsius and a maximum wavelength of 254 nm.

Experimental Animals

This study made use of forty-two (42) male neonates' albino Wistar rats (weighing 23 g on average), immediately weaned after twenty-five (25) days old. Neonates could serve as a model of early induction of obesity and in order to have accurate and pure responses, male rats were chosen to eliminate problems of hormonal imbalances in females. The University of Nigeria's Department of Zoology and Environmental Studies provided the rats that were bought. The colony cages were well-aired and maintained constant temperatures and relative humidity levels. One week was allowed for acclimatization before the experiment

began, during which time they were fed clean water and standardized palletized feed. Zimmermann's (1983) ethical standards for investigating experimental pain in conscious animals as well as the fundamentals of laboratory animal care were adhered to.

Induction of Obesity and Adiposity Index

$$\text{Lee indices of animal} = \frac{\sqrt[3]{\text{Body Weight (g)}}}{\text{Nose to Anus Length (cm)}} \quad (2)$$

Rat with a Lee index ≥ 0.3 was considered obese.

Rat body weight was measured using a weighing balance while a standard measuring tape was used to measure their nasal to anal length (cm). MSG was administered intraperitoneally from days 32, 34, 36, 38, 40 and 42. While groups III - V were fed various

On day 32, the study commenced, and the body weight of rats on days 25 (arrival day), 32, 34, 36, 38, 40 and 42 was calculated. 5 mg/g body weight of monosodium glutamate (MSG) was used to induce obesity. Following the creation of obesity in group II, the rats' length and body weight were measured and used to calculate the Lee indices using the Nakagawa *et al.* (2000) technique, which includes the formula;

enriched diets for 14 days and blood samples and tissues were collected for analysis before treatment with FLJ and honey.

Adiposity Index

This was calculated by the formula below:

$$\text{Adiposity index (\% AI)} = \frac{\text{Total weight of epididymal, visceral, and retroperitoneal fat}}{\text{Body weight}} \times 100 \quad (3)$$

Experimental Design and Animal Grouping

The experimental design was carried out in two phases. 54 male newborns in total In this investigation, Wistar albino rats were utilized. The rats were split into three groups of eighteen rats each during phase I, which involved inducing obesity. In phase II, the obese groups (groups II and III) and the control group were reassembled into seven groups of six rats each, after treatment with FLJ, MIX, and MFLJ. Rats were ultimately slaughtered, and tissues and blood samples were taken for biochemical examination.

With the help of an oral intubation tube, the extracts were administered orally. Below is a summary of the groups and dosages that were provided;

Phase I

Group I: Control, fed normal feed and clean water.

Group II: Administered intraperitoneally 5 mg/kg body weight monosodium glutamate

Group III: Fed animal protein enriched diet.

Phase II

At phase II (treatment with FLJ, MIX, and MFLJ), rats were regrouped into groups of 6 rats each as follows;

Group 1: Control, fed normal feed and clean water.

Group 2: MSG^a obese rats were orally administered 250 mg/kg fresh lime juice (FLJ)

Group 3: MSG^b obese rats were orally administered 50% FLJ and 50% honey mixture (250 mg/kg) (MIX)

Group 4: MSG^c obese rats were orally administered 200 mg/kg methanol flavonoid-rich fraction of lime juice (MFLJ)

Group 5: Animal protein enriched diet obese rats^a were orally administered 250 mg/kg fresh lime juice (FLJ)

Group 6: Animal protein enriched diet obese rats^b were orally administered 50% FLJ and 50% honey mixture (250 mg/kg) (MIX)

Group 7: Animal protein enriched diet obese rats^c, were orally administered 200 mg/kg methanol flavonoid-rich fraction of lime juice (MFLJ)

Blood and Tissue Collection

Following an overnight fast, blood was drawn via heart puncture under light chloroform anesthesia and placed into plain and EDTA tubes. Retro fraction was used to separate the serum. The whole blood was centrifuged at 5000 rpm for 10 minutes in order to separate the plasma from the erythrocytes. After removing the liver organ and adipose tissue, they were promptly weighed, wiped dry, and rinsed with regular saline. Every sample was kept at -20°C until it was examined.

Routine Determination of Body Weight of Rat

At induction of obesity (phase I) body weight of rats was taken at 25 (arrival day), 32, 34, 36, 38 40, and 42 days. The average body weight of neonates before and after obesity induction was measured to be (25 – 133 g). The average body weight of rats during treatment with FLJ, MIX, and MFLJ was measured to be (67 – 130 g). Treatment phase (II) lasted for eleven days and the body weight of rats was taken on the 1st day, 7th day, and 11th day.

Determination of Liver Function Parameters

Randox kits were used to measure the liver function parameters by the method Henry *et al.* (1974).

Determination of Renal Function Parameters

The renal function parameters were determined with the use of a Randox Kit. The following were determined; serum creatinine and urea by Bartels and Bohmer (1972).

Histopathological Examination of Adipose and Liver Tissue

A thorough observation was done on the adipose and liver tissues harvested. This was checked for anomalies and lesions that may

$$\text{ROW} = \frac{\text{Absolute Organ Weight (g)}}{\text{Body Weight of Rat on Sacrifice Day (g)}} \times 100 \quad (4)$$

Organs were preserved for further histological analysis using 10% buffered formalin after weighing. Following tissue embedding in paraffin, slices were cut using a rotary microtome at a thickness of 4-5 microns, stained with hematoxylin, and seen under a microscope.

Statistical Analysis

In SPSS version 20, raw laboratory data was analyzed using the T-test pare-wise comparison of means, along with one-way and two-way analysis of variance (ANOVA). We were given the mean \pm SEM for the results. The significant means were found at the 95% probability level using Duncan's novel multiple-range test. It was considered significant when the mean value was $p < 0.05$.

have resulted from the administration of MSG, a diet high in protein, FLJ, MIX, and MFLJ (Jain *et al.*, 2020). After that, the organs were meticulously cleaned in a 10% formaldehyde solution, dried, and weighed. An equation was used to determine each organ's relative organ weight (ROW):

Results and Discussion

HPLC Analysis of Methanol Flavonoid-Rich Fraction of Lime Juice (MFLJ)

Five distinct flavonoid compounds were found in **Table 1** when the methanol flavonoid-rich fraction of lime juice (MFLJ) was analyzed using HPLC. Quercetin, p-coumaric acid, gallic acid, caffeic acid, and sinapic acid are a few of these. After gallic acid and caffeic acid, p-coumaric acid had the highest concentration. The results of the HPLC analysis of MFLJ (**Figure 1**) indicate that the greatest peak values were obtained by p-coumaric acid and gallic acid, with concentrations of 54.23 (mg/100g) and 22.16 (mg/100g), respectively.

Table 1. HPLC – analyzed flavonoid compounds in methanol flavonoid-rich fraction of lime juice (MFLJ)

Peak No	Peak ID	Ret Time	Height	Area	Conc (mg/100g)
1	p-coumaric acid	2.915	28538.189	2468514.000	54.2333
2	Caffeic acid	1.698	18302.734	678717.000	14.9114
3	Gallic acid	1.090	53136.008	1008833.000	22.1641
4	Sinapic acid	5.465	5682.101	323112.219	7.0988
5	Quercetin	6.015	1564.842	72479.273	1.5924

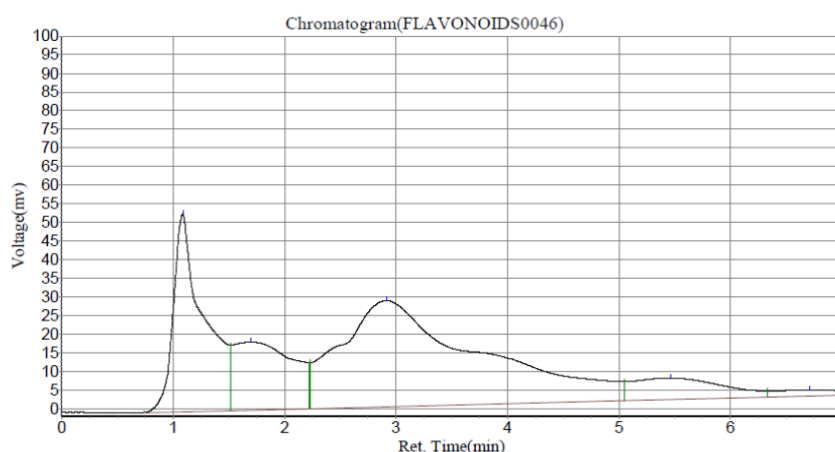


Figure 1. Chromatogram profile of methanol flavonoid-rich fraction of lime juice (MFLJ) in HPLC analysis.

Liver Function Enzymes Assay and Kidney Function Parameters

Comparing rats treated with FLJ, MIX, and MFLJ with AOI, AST, and ALT activity, as well as D-BIL and T-BIL concentrations, were significantly ($P < 0.05$) decreased. No significant ($P < 0.05$) difference was seen when compared with normal control.

Comparing the total protein (TP) concentration of rats treated with MIX with normal control and AOI, it was shown to be significantly higher ($P < 0.05$) in rats treated with MSG-obese (**Figure 2**). However, no significant increase was seen in MFLJ-treated rats. Although there was no significant ($P < 0.05$) change in D-BIL and T-BIL concentrations with FLJ, MIX, and MFLJ treatments, there

was a significant ($P < 0.05$) drop in AST and ALT activity as compared to control and AOI.

MSG obese rats treated with MFLJ had significantly ($P < 0.05$) greater amounts of creatinine, urea, and potassium than control and AOI rats (**Figure 3**). When AOI and FLJ, MIX, and MFLJ therapy was given to PRT-obese rats, there was no significant ($P < 0.05$)

change in Cl concentration. However, when compared with control, treatment with FLJ, MIX, and MFLJ significantly ($P < 0.05$) decreased Cl concentration (**Figure 4**). Treatment with FLJ, MIX, and MFLJ considerably ($P < 0.05$) decreased Cl levels in MSG-obese rats when compared to control, but significantly ($P < 0.05$) increased Cl concentration when compared to AOI.

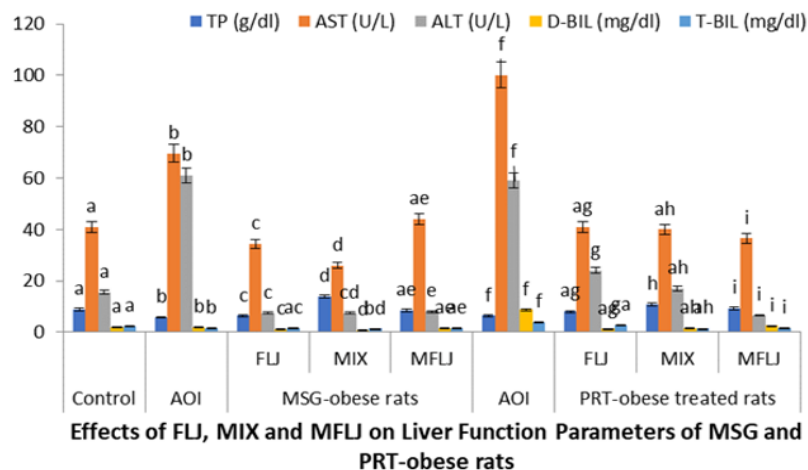


Figure 2. Effects of FLJ, MIX, and MFLJ on serum TP, AST, ALT, D-BIL, and T-BIL of MSG-obese-treated rats and Protein enriched diets-obese treated rats

The mean \pm standard error is used to compare the normal control group with the MSG-obese-treated rats, the PRT-obese-treated rats, treated FLJ, MIX, and MFLJ at the significant ($P < 0.05$) level, and the number of rats (6). Important: Rats given MSG were obese; rats given PRT were fat; rats given monosodium glutamate were obese. Obese rats fed a diet high in protein; FLJ stands for fresh

lime juice; MIX for a mixture of 50% FLJ and 50% RH; and MFLJ for a lime juice fraction rich in methanol and flavonoids. Aspartate aminotransferase (AST), alanine aminotransferase (ALT), and total protein (TP) T-BIL, or total bilirubin, and D-BIL, or direct bilirubin.

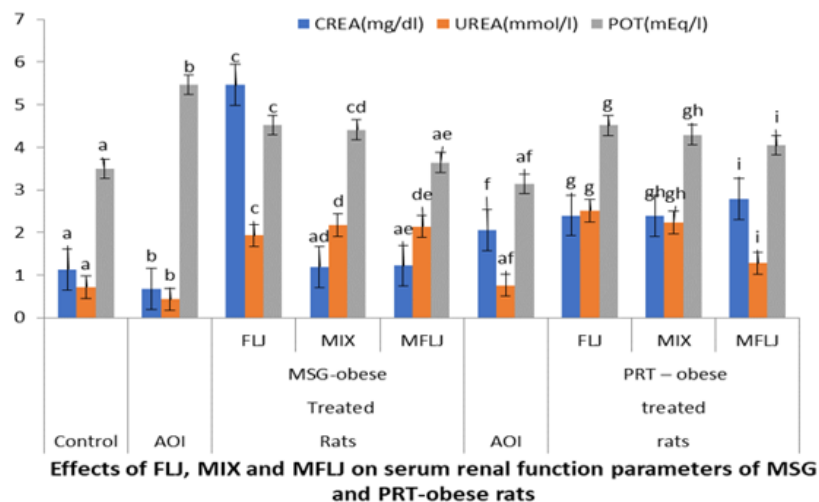


Figure 3. Effects of FLJ, MIX, and MFLJ on serum CREA, Urea, and POT of MSG- obese treated rats and Protein enriched diets-obese-treated rats

Results are Mean \pm SEM; Comparing normal control with AOI group, MSG-obese treated rats, and PRT- obese treated rats, treated FLJ, MIX, and MFLJ at the level of significant ($P < 0.05$), and (n=6). Key: MSG-obese treated rats: Monosodium glutamate

obese treated rats; PRT-obese treated rats: Protein-enriched diet obese treated rats; FLJ: Fresh Lime Juice; MIX: Mixture of FLJ (50%) and RH (50%); MFLJ: Methanol flavonoid Rich fraction of Lime Juice; CREA: Creatinine and POT: Potassium

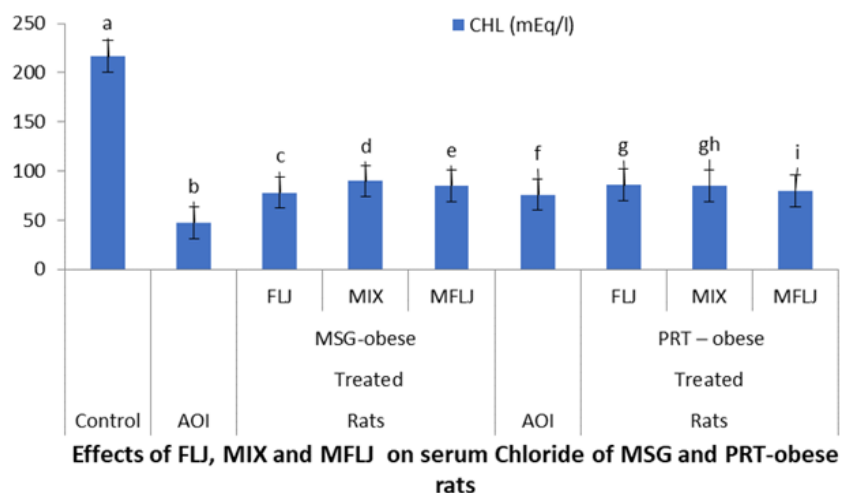


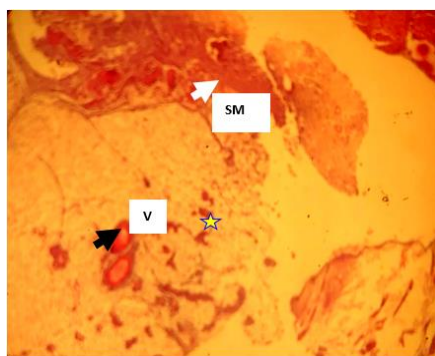
Figure 4. Effects of FLJ, MIX, and MFLJ on serum Chloride of MSG- obese treated rats and Protein enriched diets-obese-treated rats

Results are Mean \pm SEM; Comparing normal control with AOI group, MSG-obese treated rats, and PRT- obese treated rats, treated FLJ, MIX, and MFLJ at the level of significant ($P < 0.05$), and ($n=6$). Key: MSG-obese treated rats: Monosodium glutamate obese treated rats; PRT-obese treated rats: Protein-enriched diet obese treated rats; FLJ: Fresh Lime Juice; MIX: Mixture of FLJ (50%) and RH (50%); MFLJ: Methanol flavonoid Rich fraction of Lime Juice; CHL: Chlorine (Chowdhury *et al.*, 2024; Israilova *et al.*, 2024; Melkumyan *et al.*, 2024; Mohammadi *et al.*, 2024; Rohmani & Pangesti, 2024).

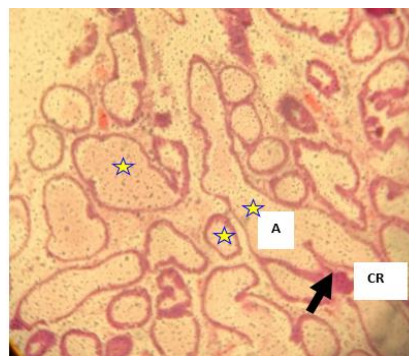
Histological Examination of Adipose and Liver Tissues

Histopathological examination showed that adipose and liver tissues from MSG-obese rats and protein-enriched diet-obese rats (**Figure 5**) presented an increase in varied size of adipocytes due to the fat droplets accumulated within them. Meanwhile, the adipose section from rats fed a normal diet (control plate1) and treated with MIX: Mixture of FLJ (50%) and RH (50%) and MFLJ:

Methanol Fraction of Lime Juice (**Figure 5**), (plates 4-6), showed completely absence adipocytes (control-plate1) and scanty adipocytes with a loss of organization mostly in small lobules. A few univacuolated small-size adipocytes were present and a partially filled lipid droplet was seen. The presence of skeletal muscles, smooth muscles, and connective tissues was observed with the normal presentation of tissue architecture. Blood vessels were observed and vascularized (plates 4 – 6). The liver section from the control group had a normal morphological appearance (**Figure 5**), (plate 1). However, livers from MSG and protein-enriched diet-obese rats showed enlarged sinusoids, congestion of the sinusoids with clogged erythrocytes, severe fat droplets characterized by micro and microvesicles, and hepatocytes displaced by the fat accumulation. Treatment with FLJ, MIX, and MFLJ, revealed restoration of hepatic tissue to normal or mild degree of necrosis and slight lymphocyte infiltration, closely related to a control group with normal hepatic strands; hepatocytes were found to be intact and properly arranged from the central vein and were seen to be demarcated by sinusoids.



a) Plate 1



b) Plate 2

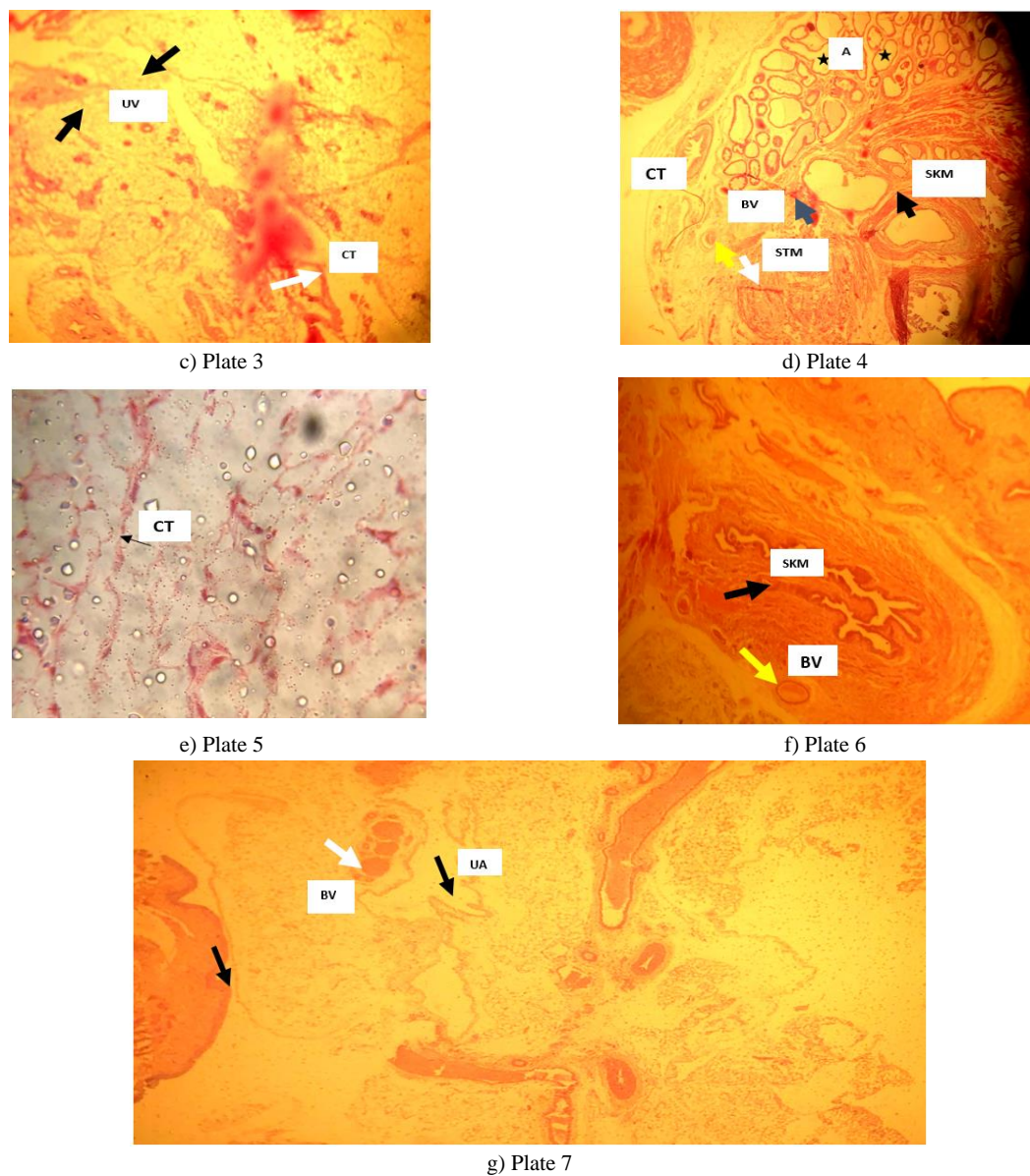
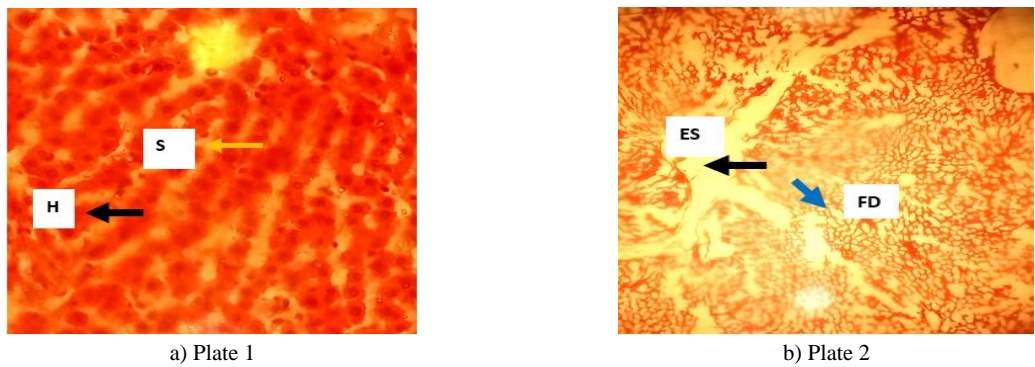


Figure 5. Effects of MIX and MFLJ on Adipose Tissue of MSG and Protein enriched diet obese rats (Plates 1-6). a) Control, b) MSG-Obese, c) PRT-Obese, d) MSG-Obese Treated MIX, e) MSG-Obese Treated MFLJ, f) PRT Enriched Diet Obese Rat Treated MIX MIXTreatedn, g) PRT Enriched Diet Obese Rat Treated MFLJ MIXTreatedn



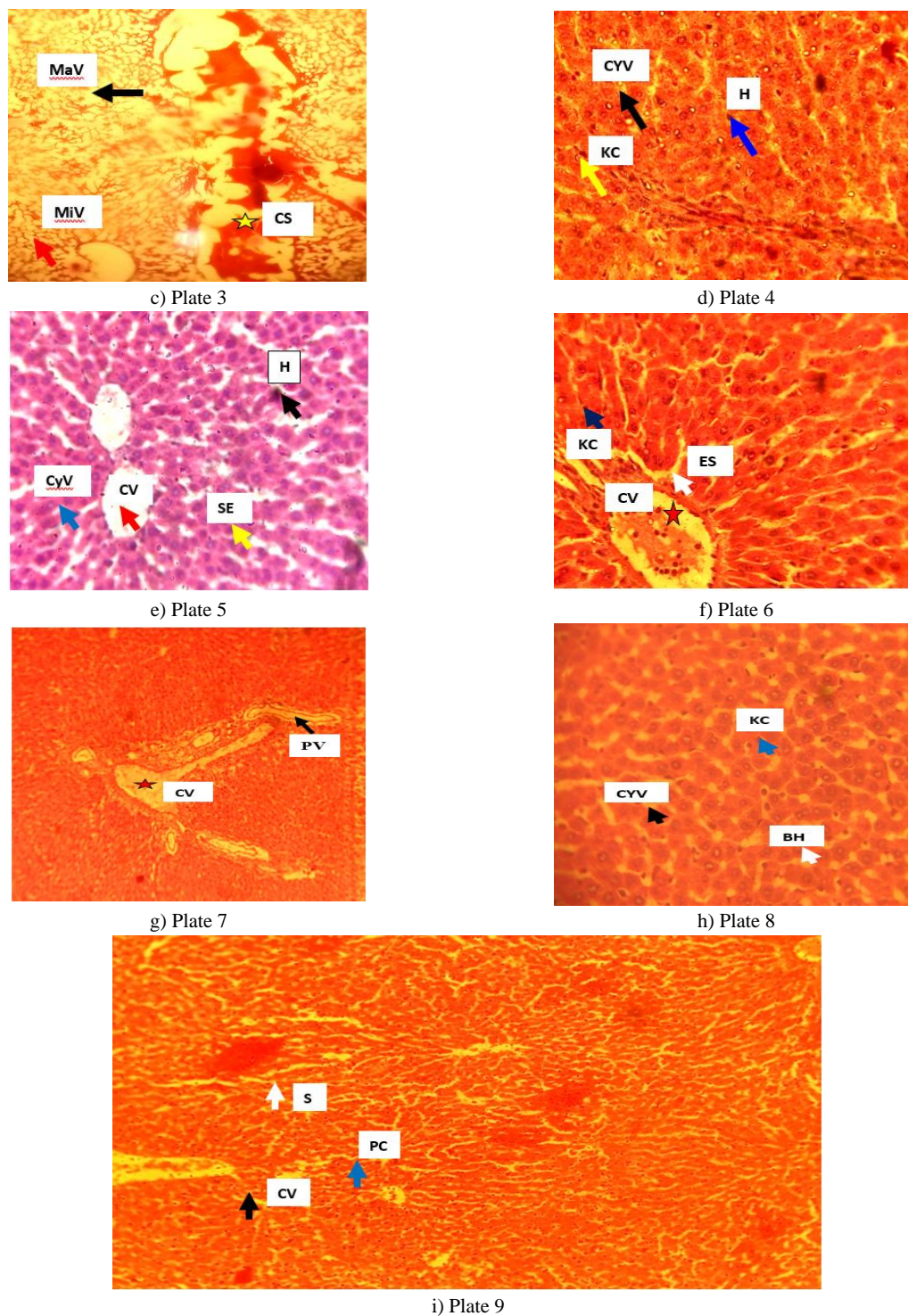


Figure 6. Effects of FLJ, MIX, and MFLJ on the liver of MSG and PRT-enriched diet obese rats (plates 1-9).

Gallic acid, caffeic acid, p-coumaric acid, sinapic acid, and quercetin are among the flavonoids in MFLJ that were studied in this study (**Table 1, Figure 1**). This is consistent with studies by Shagun *et al.* (2020) and Danila *et al.* (2018), which demonstrate that flavonoids with notable anti-inflammatory, antitumor, anticancer, anti-prostatitis, anti-allergic, and antiasthmatic properties can be found in lime juice and honey (Adhayanti *et al.*, 2024; Maloku *et al.*, 2024; Sugiaman *et al.*, 2024; Toktobolotovna

et al., 2024; Verevkina *et al.*, 2024). Flavonoids are recognized for their numerous therapeutic benefits, including their ability to act as cytoprotectors, free radical scavengers, antioxidants, and anti-inflammatory agents (Mahmoud *et al.*, 2019). Gallic acid in Indian gooseberry fruit was reported to effectively reduce accumulation of fat in adipose tissue, enhanced memory and learning; and suggested a mechanism of the gut-brain route through which cognitive decline in obese rats was inhibited (Chen *et al.*, 2023).

The association of the antioxidant capacities of gallic acid, catechin, ferulic acid, procyanidin and epicatechin-3-gallate, FRAP, DPPH, and ABTS was reported by Soheil *et al.* (2023), to be greatly related. The anti-obesity effect of epigallocatechin was associated with its ability to reduce fat accumulation in the liver and inhibit acetyl Co-A carboxylase 1 and fatty acid synthase (Sadr *et al.*, 2023). Caffeic acid was said to possess hypolipidemic, anti-inflammatory effects, anti-cancer ability, and hypoglycemic abilities and effectively manage blood pressure in hypertensive rats (Agunloye *et al.*, 2019; Okafor *et al.*, 2022).

Widely studied therapeutic phytochemicals called flavonoids have been linked to a lower risk of obesity and the morbidities that go along with it, such as non-alcoholic fatty liver disease (NAFLD) (Al-Ishaq *et al.*, 2019), type 2 diabetes (Caro-Ordieres *et al.*, 2020), cardiovascular disease (Hussain *et al.*, 2020), and cognitive disorders like Alzheimer's disease (AD) and cerebrovascular dysfunction (Sandoval *et al.*, 2020). The mechanisms of flavonoids' weight-reducing and anti-obesity ability are thought to be due to their satiety and reduction of food intake, by stimulating the release of gastrointestinal tract peptide hormones in the presence of digesting food and at the same time, reduces food intake (Sandoval *et al.*, 2020). Flavonoids enhance sustained satiety by improving the oxidation of nutrients in hepatic cells and furnishing increased nutrient concentrations in circulating blood (Fabiya-Edebor, 2020; Sandoval *et al.*, 2020).

The liver function characteristics of rats fed MSG and rats fed PRT for obesity are shown in **Figure 2**. The results of Úrsula *et al.* (2020), who observed that healthy rats given fruit purees had larger amounts of total protein and albumin than obese rats, are corroborated by the present investigation. These findings align with the result of El-Haskoury *et al.* (2019), which discovered that the aqueous and ethyl acetate extracts of carob honey in streptozotocin-induced diabetic rats exhibited reduced activities in serum AST, ALT, and ALP. Obiajulu *et al.* (2022), discovered that the three groups of rats administered different dosages of citrus aurantifolia fruit juice had significantly ($p < 0.05$) decreased activities in serum AST, ALT, and ALP. The state of the liver's health and function is intimately related to the cellular cytoplasmic release of ALT (Ezeigwe *et al.*, 2020, 2022). Therefore, the higher blood activity of ALT, AST, and ALP in the various obesity models in this inquiry suggests hepatocellular injury compared to the non-obese control and treated rats. ALP has been identified as an infrequent indicator of liver fibrosis, while ALT and AST have been defined as indicators of inflammation in hepatotoxicity (Khormi *et al.*, 2022). It was discovered that flavonoids, by scavenging free radicals, lessened damaged tissues in the treated obese rats (the histological investigation on adipose and liver tissues), (**Figures 5 and 6**). Because of this, a drop in metabolites may also indicate that cellular architecture is being restored in tissue where there is a reduction in free radicals (Morales-Ávila *et al.*, 2020).

The results of this study are consistent with the research of Úrsula *et al.* (2020), which showed that the serum concentrations of T-Bil and D-Bil in obese rats were higher than those in healthy control rats and rats fed fruit purees. Obesity and serum bilirubin levels are positively correlated (Takei *et al.*, 2019) because there is no direct or dependent relationship between body mass index or obesity and

serum bilirubin levels (Khoei *et al.*, 2018). On the other hand, low blood T-Bil concentration was linked to a 20% and 27% reduction in the risk of type 2 diabetes for both moderate and high serum T-Bil concentration obese adults, according to a stratified body mass index analysis (Wei *et al.*, 2021).

Akpevwoghene *et al.* (2022) reported consistently that the amounts of creatinine and urea in test rats were considerably ($p < 0.05$) greater than in control. According to Bamidele *et al.* (2019), rats with arthritis treated with lime juice or a combination of lime juice and maize husk extract had considerably ($p < 0.05$) lower blood urea and creatinine values. It has been noted that the burden of renal disease is increased by the rising incidence of obesity (Apetrii *et al.*, 2021) and that rat models are useful instruments for inducing experimental obesity (Eleazu *et al.*, 2022). Since creatinine and urea are exclusively used to assess renal function, they are rarely utilized as indicators of toxicity because they are metabolic waste products (Idoko *et al.*, 2023). The amount of creatinine in the blood indicates a balance of its synthesis and removal by the renal system (Idoko *et al.*, 2020). The increased serum urea concentration in treated rats might be due to the rich content of protein and amino acids in honey and FLJ. In contrast to animal-based protein diet sources, the intake of honey and fresh lime juice (MIX) as protein supplementary diet sources could inhibit heart disease and renal disease (Apetrii *et al.*, 2021). Thus, because urea is produced from catabolism of dietary protein, serum urea concentration could have increased (Idoko *et al.*, 2020, 2023). In renal dysfunction, suitable and adequate nutrient intake such as protein, minerals, vitamins, and calories is essential to prevent deterioration of the kidney (Ikizler *et al.*, 2020; Idoko *et al.*, 2023). The concentration of serum K in FLJ, MIX, and MFLJ-treated rats was significantly ($p < 0.05$) higher than control and AOI rats. This study supports the findings of Ikizler *et al.* (2020), who found a substantial correlation between weight loss and a lower BMI and an increase in dietary consumption of K. The electrolyte-protective properties of FLJ, MIX, and MFLJ are thus conferred by the observation of Citrus aurantifolia fruit juice and honey in this regard, promoting cellular electrolyte equilibrium (Ezeigwe *et al.*, 2022). In the muscles, nerves, and heart, potassium and sodium are important cellular cations, and a decrease in the concentration of these cations as observed in this research implies the modulating function of Citrus aurantifolia fruit juice and honey in the balance of electrolytes (Agbatutu *et al.*, 2022; Garagarza *et al.*, 2022).

Mohd *et al.* (2018) reported that urine chloride concentrations in rats given a high-fat diet were higher than in normal control rats. Obiajulu *et al.* (2022) reported that giving citrus aurantifolia fruit juice to test rats did not significantly ($p < 0.05$) alter their serum chloride concentrations in comparison to normal control rats. It is said that a systemic decrease in sodium will also imply a decrease in chloride concentration, and reduced chloride concentration would imply serious abnormal homeostasis (Cuthbert *et al.*, 2020). However, the results of this study revealed neither hypochloremia nor hyperchloremia in the various treated groups (Diribsa *et al.*, 2019).

Histological examination of the adipose tissue of MSG and protein-obese rats showed that adipocytes with increased size and number were observed (**Figure 6**), (plates 2 and 3). Nonetheless, the adipose tissue section of control (**Figure 6**), (plate 1) and obese

treated rats (**Figure 6**), (plates 4, 5, 6, and 7) revealed scanty adipocytes with restored vascularization and tissue architecture (Alkhalifah *et al.*, 2021; Suleiman *et al.*, 2022). Similarly, the histopathological evaluation of obese rats' livers (**Figure 6**), (plates 2 and 3) in this study revealed severe fat deposits characterized by micro and macrovesicles, and hepatocytes are displaced by the fat accumulation. While the liver of control rats (**Figure 6**), (plate 1) showed normal liver architecture characterized by intact hepatocytes, arranged in hepatic cords sinusoids, and no damage was observed. The liver of obese treated rats (**Figure 6**), (plates 4 – 9) revealed intact hepatocytes and Kupfer cells, with restored architectural features almost similar to the control rats (Terzo *et al.*, 2020).

Conclusion

We may conclude that MFLJ, and MIX process medicinal flavonoid compounds such as gallic acid, caffeic acid, p-coumaric acid, sinapic acid, and quercetin of pharmacological potentials and possible therapy for the management of hepatic and renal dysfunctions in obesity.

Acknowledgments: None

Conflict of interest: None

Financial support: None

Ethics statement: The Ethical Committee for Conduction of Animal Studies at the Faculty of Biological Sciences, University of Nigeria Nsukka with the reference number: UNN/FBS/EC/1051 approved the experimental protocol and all animals were cared for following the principles and guidelines of the committee.

References

- Adhayanti, I., Bahar, M., & Wahyudin, E. (2024). Understanding knowledge and attitudes toward self-medication: an analysis of sociodemographic factors. *Journal of Advanced Pharmacy Education and Research*, 14(3), 109-118. doi:10.51847/rfVdtyFW1s
- Agbatutu, A., Asiwe, J. N., & Adebayo, O. G. (2022). Liver and renal cell damage following excess bee honey consumption in male Wistar rat. *Biology, Medicine, & Natural Product Chemistry*, 11(1), 35-43.
- Agunloye, O. M., Oboh, G., Ademiluyi, A. O., Ademosun, A. O., Akindahunsi, A. A., Oyagbemi, A. A., Omobowale, T. O., Ajibade, T. O., & Adedapo, A. A. (2019). Cardio-protective and antioxidant properties of caffeic acid and chlorogenic acid: Mechanistic role of angiotensin converting enzyme, cholinesterase and arginase activities in cyclosporine induced hypertensive rats. *Biomedicine & Pharmacotherapy*, 109, 450-458.
- Al-Ishaq, R. K., Abotaleb, M., Kubatka, P., Kajo, K., & Büsselberg, D. (2019). Flavonoids and their anti-diabetic effects: Cellular mechanisms and effects to improve blood sugar levels. *Biomolecules*, 9(9), 430.
- Alkhalifah, M. K., Alabduljabbar, K. A., & Alkhenizan, A. H. (2021). Effect of natural honey on lowering lipid profile. *Saudi Medical Journal*, 42(5), 473-480.
- Al-Rimawi, F., Alakhras, F., Al-Zereini, W. A., Aldal'in, H. K., Abu-Lafi, S., Al-Mazaideh, G. M., & Salman, H. J. A. (2018). HPLC analysis of chemical composition of selected Jordanian medicinal plants and their bioactive properties. *Oriental Journal of Chemistry*, 34, 2397-2403.
- Ansari, M. N., Ganaie, M. A., Khan, T. H., Samad, A., Madkhali, H. A., & Ahamad, S. R. (2018). Evaluation of the diuretic potentials of naringenin in hypercholesterolemic rats. *Tropical Journal of Pharmaceutical Research*, 17(2), 239-244.
- Apetrii, M., Timofte, D., Voroneanu, L., & Covic, A. (2021). Nutrition in chronic kidney disease—The role of proteins and specific diets. *Nutrients*, 13(3), 956.
- Bartels, H., & Bohmer, M. (1972). In vitro determination of creatinine and urea. *Clinical Chemistry*, 2, 37-193.
- Bich, T. N. T., Doan, D. T., Hai, H. N., Ha, T. N. T., & Thi, N. N. (2023). Impact of behavioral factors on the stock investment decisions of generation Z in Vietnam. *Journal of Organizational Behavior Research*, 8(2), 129-143. doi:10.51847/jJBx9EABdo
- Caro-Ordieres, T., Marín-Royo, G., Opazo-Ríos, L., Jiménez-Castilla, L., Moreno, J. A., Gómez-Guerrero, C., & Egido, J. (2020). The coming age of flavonoids in the treatment of diabetic complications. *Journal of Clinical Medicine*, 9(2), 346.
- Chen, Y. Y., Chen, S. Y., Lin, J. A., & Yen, G. C. (2023). Preventive effect of Indian gooseberry (*Phyllanthus emblica* L.) fruit extract on cognitive decline in high-fat diet (HFD)-fed rats. *Molecular Nutrition & Food Research*, 67(7), 2200791. doi:10.1002/mnfr.202200461
- Chowdhury, F., Dube, R., Riyaz, R., Khan, K., Al-Zuheiri, S. T. S., & Rangraze, I. R. (2024). Title-efficacy of metformin as monotherapy in gestational and pre-gestational diabetic pregnant women. *Journal of Advanced Pharmacy Education and Research*, 14(2), 84-90. doi:10.51847/QoUS4cqLD6
- Cianciosi, D., Forbes-Hernández, T. Y., Afrin, S., Gasparini, M., Reboredo-Rodríguez, P., Manna, P. P., Zhang, J., Bravo Lamas, L., Martínez Flórez, S., Agudo Toyos, P., et al. (2018). Phenolic compounds in honey and their associated health benefits: A review. *Molecules*, 23(9), 2322.
- Cuthbert, J. J., Bhandari, S., & Clark, A. L. (2020). Hypochloroemia in patients with heart failure: Causes and consequences. *Cardiology and Therapy*, 9(2), 333-347.
- Darwish, A. G., Moniruzzaman, M., Tsoola, V., & El-Sharkawy, I. (2023). Integrating metabolomics and gene expression underlying potential biomarkers compounds associated with antioxidant activity in southern grape seeds. *Metabolites*, 13(2), 210. doi:10.3390/metabo13020210
- Diriba, G. C., Kinfe, Y. A., & Abdissa, S. G. (2019). Assessment of renal function and electrolyte balance in patients with cardiovascular disease at Tikur Anbessa Specialized hospital, Addis Ababa, Ethiopia. *Scientific Journal of Medical Research*, 3(10), 70-78.
- Eleazu, C., Suleiman, J. B., Othman, Z. A., Zakaria, Z., Nna, V. U., Hussain, N. H. N., & Mohamed, M. (2022). Bee bread attenuates high fat diet induced renal pathology in obese rats

- via modulation of oxidative stress, downregulation of NF- κ B mediated inflammation and Bax signalling. *Archives of Physiology and Biochemistry*, 128(4), 1088-1104.
- El-Haskoury, R., Al-Waili, N., El-Hilaly, J., Al-Waili, W., & Lyoussi, B. (2019). Antioxidant, hypoglycemic, and hepatoprotective effect of aqueous and ethyl acetate extract of carob honey in streptozotocin-induced diabetic rats. *Veterinary World*, 12(12), 1916-1923.
- Ezeigwe, O. C., Ani, O. N., & Okafor, M. C. (2022). Toxicological studies of Citrus aurantifolia fruit juice in Wistar rats. *Asian Journal of Biochemistry, Genetics and Molecular Biology*, 10(4), 38-47.
- Ezeigwe, O. C., Nzekwe, F. A., Nworji, O. F., Ezennaya, C. F., Iloanya, E. L., & Asogwa, K. K. (2020). Effect of aqueous extract of F. capensis leaves and its combination with C. aconitifolius leaves on essential biochemical parameters of phenylhydrazine-induced anemic rats. *Journal of Experimental Pharmacology*, 12, 191-201.
- Fabiyi-Edebor, T. D. (2020). Anti-obesity and anti-lipidemic properties of ascorbic acid in fructose induced obese Wistar rats. *European Journal of Medical and Health Sciences*, 2(5), 1-4.
- Garagarza, C., Valente, A., Caetano, C., Ramos, I., Sebastião, J., Pinto, M., Oliveira, T., Ferreira, A., & Guerreiro, C. S. (2022). Potassium intake—(Un) expected non-predictor of higher serum potassium levels in hemodialysis DASH diet consumers. *Nutrients*, 14(10), 2071.
- Grzesik, M., Naparło, K., Bartosz, G., & Sadowska-Bartos, I. (2018). Antioxidant properties of catechins: Comparison with other antioxidants. *Food Chemistry*, 241, 480-492.
- Henry, R. J. (1974). *Clinical chemistry: Principles and technics*. 2nd ed. Harper and Row, Hagerstown, M.D.
- Hussain, T., Tan, B., Murtaza, G., Liu, G., Rahu, N., Kalhor, M. S., Kalhor, D. H., Adebawale, T. O., Mazhar, M. U., ur Rehman, Z., et al. (2020). Flavonoids and type 2 diabetes: Evidence of efficacy in clinical and animal studies and delivery strategies to enhance their therapeutic efficacy. *Pharmacological Research*, 152, 104629.
- Idoko, A. (2019). Exploitative beneficial effects of citrus fruits. In: M. S. Amanullah (Ed.), *Citrus - Health Benefits and Production Technology* (pp. 32-55). IntechOpen.
- Idoko, A., Ezech, E. M., Philip, O. C., Nwali, O. N., Ugwu-dike, P. O., Agu, P. C., Ayomide, T. A., Onyinye, A. N., & Blessing, N. O. (2023). Raw and cooked aqueous and methanol extracts of Vigna unguiculata (black-eyed bean) enhances renal function in experimental Wistar rats. *Nutrition & Food Science*, 53(7), 1147-1165. doi:10.1108/NFS-07-2022-0221
- Idoko, A., Philip, O. C., Nwali, O. N., Ugwu-dike, P. O., Blessing, N. O., Onyinye, A. N., Ani, P. N., & Ayomide, T. A. (2020). Effects of raw and cooked aqueous and methanol extracts of Phaseolus vulgaris (kidney beans) on renal function in albino Wistar rats. *Universal Journal of Pharmaceutical Research*, 5(3), 6-11. doi:10.22270/ujpr.v5i3.408
- Ikizler, T. A., Burrows, J. D., Byham-Gray, L. D., Campbell, K. L., Carrero, J. J., Chan, W., Fouque, D., Friedman, A. N., Ghaddar, S., Goldstein-Fuchs, D. J., et al. (2020). KDOQI clinical practice guideline for nutrition in CKD: 2020 update. *American Journal of Kidney Diseases*, 76(3), S1-S107.
- Israilova, R. U., Kochkarova, A. K., Makhauri, L. G., Abakarov, I. A., Yusupova, L. S., Getaeva, M. S., Ananeva, V. O., & Khazbulatova, M. S. (2024). The use of biodegradable scaffold based on bacterial cellulose in the treatment of open brain injury. *Journal of Advanced Pharmacy Education and Research*, 14(2), 91-96. doi:10.51847/IXxO9AGZor
- Jain, S., Arora, P., & Popli, H. (2020). A comprehensive review on Citrus aurantifolia essential oil: Its phytochemistry and pharmacological aspects. *Brazilian Journal of Natural Sciences*, 3(2), 354-364.
- Khoei, N. S., Grindel, A., Wallner, M., Mölzer, C., Doberer, D., Marculescu, R., Bulmer, A., & Wagner, K. H. (2018). Mild hyperbilirubinaemia as an endogenous mitigator of overweight and obesity: Implications for improved metabolic health. *Atherosclerosis*, 269, 306-311.
- Khormi, M. A., Elnaggar, M. H. R., & Al-Hazmi, M. A. (2022). Protective effects of Manuka honey against diazinon induced hepatorenal toxicity in adult male rats. *Acta Scientific Medical Sciences (ISSN: 2582-0931)*, 6(6), 9-22.
- Kumbhar, S., Patil, N., Patil, B., You, H. W., & Bhatia, M. (2024). Unleashing the Power of Rutin-Loaded Nanophytosomes: Enhancing Antioxidant Potential for Improved Health Outcomes. *World Journal of Environmental Biosciences*, 13(3), 8-15. doi:10.51847/P5y5gxQ5no
- Mahmoud, A. M., Hernandez Bautista, R. J., Sandhu, M. A., & Hussein, O. E. (2019). Beneficial effects of citrus flavonoids on cardiovascular and metabolic health. *Oxidative Medicine and Cellular Longevity*, 2019(1), 5484138.
- Maloku, A., Bejiqi, R., Mustafa, A., Zeka, N., & Bejiqi, R. (2024). Nutrition of children with complex congenital heart anomalies. *Journal of Advanced Pharmacy Education and Research*, 14(3), 90-93. doi:10.51847/2xFZ3UXu51
- Melkumyan, V. A., Kurbanova, D. A., Magomedgadzhieva, R. S., Khidiryan, M. V., Eremin, S. A., Stepanenko, V. S., Dzhanakaeva, A. A., & Tanasheva, A. M. (2024). Assessment of wound-healing activity of zinc oxide nanoparticles. *Journal of Advanced Pharmacy Education and Research*, 14(1), 73-76. doi:10.51847/0SQk1Cmx1X
- Mohammadi, R. G., Rajaei, E., Ghanbaran, A., Fatemi-Behbahani, S. A., & Mowla, K. (2024). Pregnancy and neonatal outcomes in pregnant patients with inflammatory arthropathy treated by etanercept; Retrospective study. *Journal of Advanced Pharmacy Education and Research*, 14(2), 58-62. doi:10.51847/6tZIJU9kV
- Morales-Ávila, Ú. M., Becerra-Verdín, E. M., Sáyago-Ayerdi, S. G., Tolman, J. P., & Montalvo-González, E. (2020). Anti-obesity and hepatoprotective effects in obese rats fed diets supplemented with fruit purees. *Food Science and Technology*, 40, 33-41.
- Nakagawa, T., Ukai, K., Ohyama, T., Gomita, Y., & Okamura, H. (2000). Effects of chronic administration of sibutramine on body weight, food intake and motor activity in neonatally monosodium glutamate-treated obese female rats: Relationship of antiobesity effect with monoamines. *Experimental Animals*, 49(4), 239-249.
- Okafor, J. N., Meyer, M., Le Roes-Hill, M., & Jideani, V. A. (2022). Flavonoid and phenolic acid profiles of dehulled and whole Vigna subterranea (L.) Verdc seeds commonly

- consumed in South Africa. *Molecules*, 27(16), 5265. doi:10.3390/molecules27165265
- Olusolade, F. S., & Akintayo, C. O. (2014). Microbiological and physico-chemical examination of some honey samples from Southwest, Nigeria. *Journal of Advanced Botany and Zoology*, 2(1), 1-7.
- Owoyele, B. V., Ibiyemi, A. V., & Oyeleke, M. B. (2019). Anti-athritic effects of lime, maize husk extract and its co administration on Wistar rats. *Future Natural Products*, 4(4), 59-70.
- Rock, R. C., Walker, W. G., & Hennings, C. D. (1987). Nitrogen metabolites and renal function. In: N. W. Tietz (Ed.), *Fundamentals of clinical chemistry* (3rd ed., pp. 669-704). Philadelphia: WB Saunders.
- Rohmani, S., & Pangesti, T. B. (2024). Sunscreen cream formulation from a combination of propolis extract and titanium dioxide. *Journal of Advanced Pharmacy Education and Research*, 14(2), 77-83. doi:10.51847/wzPc0dCU6c
- Rotimi, O. A., Olayiwola, I. O., Ademuyiwa, O., & Balogun, E. A. (2012). Effects of fibre-enriched diets on tissue lipid profiles of MSG obese rats. *Food and Chemical Toxicology*, 50(11), 4062-4067.
- Sadr, S., Yousefsani, Z., Simab, P. A., Alizadeh, A. J. R., Lotfalizadeh, N., & Borji, H. (2023). *Trichinella spiralis* as a potential antitumor agent: An update. *World's Veterinary Journal*, (1), 65-74.
- Sandoval, V., Sanz-Lamora, H., Arias, G., Marrero, P. F., Haro, D., & Relat, J. (2020). Metabolic impact of flavonoids consumption in obesity: From central to peripheral. *Nutrients*, 12(8), 2393.
- Shahidi, F., & Hossain, A. (2023). Importance of insoluble-bound phenolics to the antioxidant potential is dictated by source material. *Antioxidants*, 12(1), 203. doi:10.3390/antiox12010203
- Singar, F. A. W. (2024). Characterization of Defatted Cake Prepared from Egyptian Olive's Fruit (Wateeken Cultivar) and Its Biological Activity. *World Journal of Environmental Biosciences*, 13(2), 31-35. doi:10.51847/R7K4g1FOdt
- Sugiaman, V. K., Pranata, B. M. D., Susila, R. A., Pranata, N., & Rahmawati, D. Y. (2024). Antibacterial activity, cytotoxicity, and phytochemicals screenings of binahong (*Anredera cordifolia* (Ten.) steenis) leaf extract. *Journal of Advanced Pharmacy Education and Research*, 14(1), 1-7. doi:10.51847/BXxQtsSI1s
- Suleiman, J. B., Mohamed, M., Abu Bakar, A. B., Zakaria, Z., Othman, Z. A., & Nna, V. U. (2022). Therapeutic effects of bee bread on obesity-induced testicular-derived oxidative stress, inflammation, and apoptosis in high-fat diet obese rat model. *Antioxidants*, 11(2), 255.
- Takei, R., Inoue, T., Sonoda, N., Kohjima, M., Okamoto, M., Sakamoto, R., Inoguchi, T., & Ogawa, Y. (2019). Bilirubin reduces visceral obesity and insulin resistance by suppression of inflammatory cytokines. *PloS One*, 14(10), e0223302.
- Terzo, S., Mulè, F., & Amato, A. (2020). Honey and obesity-related dysfunctions: A summary on health benefits. *The Journal of Nutritional Biochemistry*, 82, 108401.
- Thuy, V. T. T., Hung, D. N., Oanh, L. T. T., Tuyet, V. T. A., & Thu, B. T. (2023). Factors impact on business performance of enterprises: the case of Vietnam. *Journal of Organizational Behavior Research*, 8(2), 27-39. doi:10.51847/2itmiM3CoE
- Toktobolotovna, A. B., Nurzamana, A. K., Meerim, D. K., Sydykovna, M. E., Tezekbayevich, Z. S., Mamatoktorovna, Z. G., Turgunbaevna, S. S., & Amanovna, N. R. (2024). Comparative analysis of antimicrobial drug sensitivity in the population of Kyrgyzstan: Pre-and Post-COVID-19 pandemic. *Journal of Advanced Pharmacy Education and Research*, 14(1), 91-96. doi:10.51847/iOSmUFAAAa
- Tran, A. D., Do, L. H., & Lai, L. T. T. (2023). The impact of monetary policy on environmental pollution in a transition country: the case of Vietnam. *Journal of Organizational Behavior Research*, 8(2), 54-65. doi:10.51847/DcFBvBTVOw
- Verevkin, M., Gasparian, I., Ermakov, M., Kozlikin, A., Pavlenko, E., Pavlenko, A., Tikhonov, E., & Matyukhin, A. (2024). Milk fortification with a complex of iron with ascorbic acid for control of iron deficiency anemia. *Journal of Advanced Pharmacy Education and Research*, 14(1), 77-83. doi:10.51847/iNNlmykx5
- Wei, Y., Liu, C., Lai, F., Dong, S., Chen, H., Chen, L., Shi, L., Zhu, F., Zhang, C., Lv, X., et al. (2021). Associations between serum total bilirubin, obesity and type 2 diabetes. *Diabetology & Metabolic Syndrome*, 13, 1-7.
- Yilmaz, S., Ertürk, M., Soydemir, A., Erciyas, A., & Oran, İ. B. (2023). Military implications of artificial intelligence - case of republic of Turkey. *Journal of Organizational Behavior Research*, 8(2), 1-14. doi:10.51847/Tal2sc1FFp
- Zakaria, Z., Othman, Z. A., Suleiman, J. B., Che Jalil, N. A., Ghazali, W. S. W., Nna, V. U., & Mohamed, M. (2021). Hepatoprotective effect of bee bread in metabolic dysfunction-associated fatty liver disease (MAFLD) rats: Impact on oxidative stress and inflammation. *Antioxidants*, 10(12), 2031.
- Zimmermann, M. (1983). Ethical guidelines for investigations of experimental pain in conscious animals. *Pain*, 16(2), 109-110.