

Study of Blood-Ocular Barrier Permeability by Levomecitin Group Drugs in Normal and Pathological Conditions

Daria Andreevna Gorokhova, Karolina Karenovna Tsaturyan, Albert Armenovich Engibaryan*, Valeriia Fedorovna Bosenko, Natalia Vasilyevna Makarenko, Anna Vladimirovna Chernookova

Received: 27 January 2023 / Received in revised form: 28 May 2023, Accepted: 02 June 2023, Published online: 20 June 2023
© Biochemical Technology Society 2014-2023
© Sevas Educational Society 2008

Abstract

An eye defense mechanism called the blood-ocular barrier stops hazardous compounds from the circulatory system from entering the eye's structural components. In order to preserve human health and quality of life, the blood-ocular barrier must operate at its peak. There are several eye illnesses that might be linked to a breach in the blood-ocular barrier's functionality. The blood-ocular barrier's permeability to medications in the levomecitin group was examined in this paper under both healthy and unhealthy circumstances. A total of 40 laboratory rabbits were divided into two groups for this reason, and the experimental group's rabbits underwent artificial induction of keratoconjunctivitis. In the posterior femoral muscle group of rabbits in the control and experimental groups, a 30 mg/kg dose of a 10% chloramphenicol solution diluted in a 0.5% novocaine solution was intramuscularly administered twice, separated by a 12-hour interval. Next, the behavior and health of the rabbits in both groups were observed, along with routine checks on the animals' body temperatures, pulses, and respirations. On several experiment days, the level of chloramphenicol in blood serum and intraocular fluid was examined in order to gauge the permeability of the blood-ocular barrier. Further research was done on the biochemical and hematological characteristics of blood serum.

Keywords: Blood-ocular barrier, The permeability of blood-ocular barrier, Levomecetine, Chloramphenicol, Blood serum

Daria Andreevna Gorokhova

Department of Therapy, Faculty of Medicine of Stavropol State Medical University, Stavropol, Russia.

Karolina Karenovna Tsaturyan

Department of Therapy, Pediatric Faculty of Stavropol State Medical University, Stavropol, Russia.

Albert Armenovich Engibaryan*, Valeriia Fedorovna Bosenko, Natalia Vasilyevna Makarenko, Anna Vladimirovna Chernookova

Department of Therapy, Pediatric Faculty of Rostov State Medical University, Rostov-on-Don, Russia.

*E-mail: ruslankalmykov777@yandex.ru

Introduction

The blood-ocular barrier is a protective system of the eyeball that prevents the penetration of harmful substances from the circulatory system into the structures of the eye (Coca-Prados, 2014; Dhyani & Kumar, 2019). This barrier is formed due to the complex interaction between the cells of the vascular wall and the endothelial cells of the capillary network in the retina of the eye (Alattas *et al.*, 2019; Schoeneberger *et al.*, 2023).

Blood-ocular barrier maintains the necessary balance between resources entering the cells and tissues of the eye and toxic substances that can penetrate the eye (Iosseliani *et al.*, 2020; Alsubaie *et al.*, 2021). Most of the components of this barrier are localized at the level of capillaries in the retina, where they provide high-quality filtration and permeability of vascular walls (Lublinsky *et al.*, 2019; Ramadan *et al.*, 2019).

The effectiveness of the blood-ocular barrier is based on the close interaction between capillary endothelial cells and astrocytes that surround the capillaries of the circulatory system (Galland *et al.*, 2019). The ability to elasticity and strength of astrocyte cells enables them to provide a stable and reliable separation between blood and eye tissues, absorbing and disposing of toxic oxygen radicals and other harmful substances (Valori *et al.*, 2019).

This process is especially important for maintaining the health of the retina, which has high energy needs. Violation of the function of the blood-ocular barrier may be associated with various eye diseases, such as glaucoma, macular degeneration, inflammation, and others (Tomi & Hosoya, 2010).

Optimal functioning of the blood-ocular barrier is a prerequisite for maintaining human health and quality of life. New techniques for the identification and cure of eye illnesses can be developed by comprehending the principles behind this process, and can also be widely used in other areas of medical science and technology where protection of body tissues from exposure to harmful substances is required (Cronau *et al.*, 2010).

The permeability of the blood-ocular barrier is an important indicator of the functional state of the eye (Jordán & Ruiz-Moreno, 2013). Violation of the permeability of the barrier can lead to various eye diseases, such as diabetic retinopathy, macular



degeneration, inflammatory diseases, and others. One of the main mechanisms for maintaining the permeability of the blood-ocular barrier is the function of the capillary endothelial cells that make up the barrier. These cells determine the permeability of the barrier by regulating the permeability of the capillary walls (Garner *et al.*, 2001). Fluorescein injections are one approach for determining how permeable the blood-ocular barrier is to research. This method makes it possible to assess violations of the permeability of the barrier by the degree of penetration of fluorescein into the eye tissues (Shmyreva *et al.*, 2005). Optical coherence tomography and magnetic resonance tomography methods can also be used to study the permeability of the blood-ocular barrier (Zmyslowska *et al.*, 2019; Shevchenko *et al.*, 2020; Mezhidov *et al.*, 2021). These methods allow us to obtain more accurate information about the state of the internal structures of the eye and assess violations of the permeability of the barrier.

Liu *et al.* (2018) found that the violation of the permeability of the blood-ocular barrier is one of the leading factors in the development of many eye diseases (Liu *et al.*, 2018). Therefore, it is important to conduct regular medical examinations and use modern research methods for the early detection of barrier permeability disorders and the timely treatment of eye diseases.

The antibiotic levomycetin is frequently used to treat a variety of infectious disorders, including infections of the eyes. Conjunctivitis, keratitis, blepharitis, and other conditions may be among them. Levomycetin is used in the form of eye drops or ointments. Levomycetin eye drops contain 0.25% or 0.5% concentration of the active ingredient, and ointment – 1% or 3% concentration. These dosage forms are used depending on the severity of the disease, but in general, they are well tolerated and have a minimal risk of side effects (Smith & Weber, 1983). Levomycetin is a bacteriostatic antibiotic that inhibits protein synthesis in bacterial cells, which leads to their death (Darougar *et al.*, 1977). Due to this action, levomycetin can be used to treat various types of bacteria, including onyx, streptococcus, Staphylococcus, and others. In addition, levomycetin is highly effective in the treatment of diseases caused by multiple sensitivity of bacteria to other antibiotics (Rushford *et al.*, 1978). This is important for patients in whom antimicrobial therapy was not effective or did not give the desired result. In the treatment of eye diseases, levomycetin can be used in conjunction with other medications, such as glucocorticosteroids or antihistamines. This can enhance and accelerate the effect of treatment.

It is also worth noting that levomycetin is not the first choice medicine in the treatment of eye diseases, since in some cases other antibiotics may be more effective (Lam *et al.*, 2002). However, its use may be justified in cases where other medicines have not given the proper effect. Thus, levomycetin is an effective antibiotic in the treatment of eye infections, which can be used as one of the components of multifactorial therapy. However, to get the maximum effect, all factors of the disease should be taken into account and comprehensive treatment should be carried out.

Materials and Methods

This research investigation looks at how drugs from the levomycetin group affect the blood-ocular barrier permeability under both healthy and diseased situations of the visual organ. 40 mature rabbits without any disorders and with average development and weight participated in an experiment to achieve this. The analogy concept was used to divide the rabbits into two groups, each with 20 individuals:

- group 1 (control) - consisted of clinically healthy individuals;
- group 2 (experiment) - consisted of individuals with experimentally induced pathology of the visual organ (keratoconjunctivitis).

Every rabbit received two intramuscular injections of a 10% chloramphenicol solution diluted in a 0.5% novocaine solution at a dosage of 30 mg/kg into the posterior femoral muscle group, separated by a 12-hour interval.

Following the technique outlined in the paper, biological fluids were removed from rabbits every day after the experiment began, two hours after the morning injection (Blinov *et al.*, 2022). Chloramphenicol levels in intraocular fluid and blood serum were measured. In addition, the biochemical and hematological characteristics of the blood serum of both groups of laboratory animals were assessed on the first, third, and fifth days of the experiment in accordance with commonly established practices (Blinov *et al.*, 2023).

Animals of both groups were kept in identical conditions with the same feeding regimes. Their behavior and well-being were constantly monitored with daily measurements of temperature and heart rate (Lyashenko *et al.*, 2023).

Results and Discussion

In the experimental group, the following clinical signs of the pathology of the organ of vision were noted: edema and hyperemia of the eyelids, the iris is edematous, lacrimation is pronounced, the cornea is edematous, the conjunctiva is bright pink, edematous - 4 days of experience; precorneal injection at the needle injection site, the eyelids are calm, the cornea is transparent, the iris is edematous, the pupil reacts to light – 5 days experience.

Biological fluids were extracted from rabbits two hours after the morning treatment.

Clinical recovery occurred in all animals on the eighth day following the initiation of therapy, as evidenced by the normalization of the animals' overall condition, stability of their body temperatures, pulse rates, and various breathing movements that were also within the normal range.

In the visual analyzer, three animals from the experimental group were found to be free of inflammatory signs in the conjunctiva, cornea, and iris.

The dynamics of chloramphenicol concentrations in blood serum and intraocular fluid are shown in **Table 1**.

For a therapeutic dose of chloramphenicol, a concentration in biological fluids of 4-10 µg/mg is taken.

On day two of the study, the antibiotic concentration in the blood serum increased by 10% in the first group and by 3% in the second.

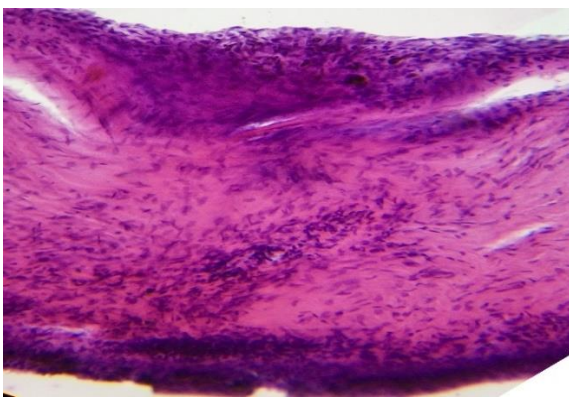
Table 1. Chloramphenicol concentration in biological fluids, $\mu\text{g}/\text{mg}$ ($n = 20$; $M \pm m$)

Research Day	Blood serum		Intraocular fluid	
	Control group	Experienced group	Control group	Experienced group
1	4.3 \pm 0.25	4.11 \pm 0.21	1.7 \pm 0.09	2.81 \pm 0.45
2	4.8 \pm 0.28	4.25 \pm 0.13	1.93 \pm 0.12	2.32 \pm 0.53
3	5.4 \pm 0.32	5.12 \pm 0.23	2.6 \pm 0.13	4.61 \pm 0.84
4	5.9 \pm 0.29	5.35 \pm 0.27	3.1 \pm 0.21	3.45 \pm 0.47
5	6.4 \pm 0.38	6.32 \pm 0.31	4.3 \pm 0.27	3.73 \pm 0.72

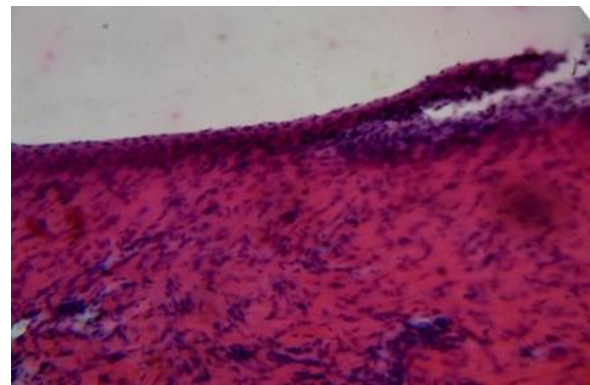
This indicator grew by 8% and 4%, respectively, on the fourth day of the trial in the clinically healthy animal group and the ill animal group. The blood serum from the second group had a positive correlation coefficient with the results from the first group ($r = 0.972$), indicating a high (near) direct association. As a result, both groups' blood serum levels of chloramphenicol throughout the trial were within the therapeutic range.

The antibiotic concentration in the intraocular fluid in the first group rose by 12%, whereas it rose by 17% in the second group on the second day of the trial. In the group of clinically healthy animals, the examined indicator had grown by 16% by the fourth day, while it had declined by 25% in the ill animals. With respect to the first group's data, the second group's intraocular fluid has a positive correlation coefficient ($r = 0.507$), indicating an average direct association. Thus, the minimal therapeutic concentration of chloramphenicol in the intraocular fluid was reached in the group of clinically healthy animals on the fifth day of the experiment and in the group of ill animals on the third day of the research.

The structures of the visual analyzer were investigated in order to better understand the structural and morphological alterations that the disease brought to the visual organ (**Figure 1**). Three healthy rabbits and three rabbits with induced pathology were killed simultaneously by decapitation, three days after infection, in all rabbit groups.



a)



b)

Figure 1. Structures of the visual analyzer:

- a) the cornea. Signs of inter-plate edema with a violation of the parallelism of the course of the stromal plates pronounced inflammatory infiltration; b) desquamation of the corneal epithelium, lymphocytic infiltration.

The second group of animals showed the following morphological changes when the morphological structures of the eye were examined: swelling of the conjunctival stroma, its lymphocytic infiltration, sclera with inflammatory infiltration phenomena, and signs of interplate edema in the cornea with a violation of the parallelism of the stromal plates, pronounced inflammatory infiltration, desquamation of the corneal epithelium, significant vasodilation in the iris, iris and ciliary processes with lymphocytic infiltration, signs of uveitis in the vascular membrane, inflammatory infiltration of the retina.

It has been determined that the vascular membrane constituting the histogenetic barrier has undergone a change in the micromorphology of the ocular structures. There was just a little inflammatory infiltrate.

Hematological and biochemical analyses of blood serum were conducted (**Tables 2 and 3**) in order to track the changes that were taking place throughout the animal's body as a whole. By the conclusion of the trial, the leukocyte count had grown by 1% in the group of clinically healthy animals and by 31% in the ill animals, both of which were within the physiological norm. Due to the

second group's elevated level of this signal, which is related to the body's response to the pathogenic agent injected.

Throughout the whole trial, the clinically healthy animal group's relative concentrations of lymphocytes, monocytes, and granulocytes were within the range of normal physiology. The body's reaction to the pathogenic agent that has been introduced is

what accounts for an increase in granulocytes and a reduction in lymphocytes in a group of ill animals. On the fifth day of the experiment, the number of erythrocytes in the group of animals that were clinically healthy showed no significant change, whereas it dropped by 21% in the group of animals that had disease of the visual organ.

Table 2. Hematological parameters of blood serum of laboratory animals, (n =20; M±m)

Indicators	Background indicators	Day 1		Day 3		Day 5	
		Control group	Experienced group	Control group	Experienced group	Control group	Experienced group
White Blood Cell, ×10 ⁹ /L	8.4±0.42	8.5±0.5	10.34 ±0.6	8.9±0.5	11.8±0.58	8.6±0.43	14.9±0.7
Lymphocyte percentage, %	44.2±2.2	47.5±2.5	44.6±2.68	44±3.3	45.6±2.74	46.8±2.7	35.4±1.8
Mid-sized cell percentage, %	3.7±0.2	3.9±0.2	4.65±0.23	3.8±0.23	4.1±0.25	4.3±0.26	3.0±0.15
Granulocyte percentage, %	52.1±2.61	49.5±2.2	51.3±2.6	52.7±3.4	50.4±3.0	49.9±2.5	62.0±3.1
Red Blood Cell, ×10 ¹² /L	6.1±0.31	6.2±0.3	6.26±0.38	6.3±0.32	5.94±0.38	5.9±0.26	4.71±0.24
Hemoglobin Concentration, g/L	133.2±6.7	134.1 ±8	142.4 ±7.12	135.3±7	112.9±5.7	132±5.6	100.4 ±5.02
Hematocrit, %	38.8±2.0	39.8±2.4	43.2±2.2	42.3±2.5	32.6±1.63	40.3±1.6	28.9±1.45
Platelet, ×10 ⁹ /L	375.1±19.0	393.2±7	227.5±11.0	394.4±3	236.8±5.0	382.1±15	234.4±12.0

By the fifth day, the clinically healthy group of animals showed no significant changes in hemoglobin concentration, while the ill group showed a 21% fall in this parameter. A significant decrease in hematocrit in the second group indicates a lack of red blood cells in the blood, which is explained by their hemolysis (Kaneko *et al.*, 2021).

Following the most recent blood draw, the number of platelets in the clinically healthy animal group fell by 3%, while it rose by 3% in the group of animals with disease of the eye, both of which were within the range of the physiological norm.

Table 3. Biochemical parameters of blood serum of laboratory animals, (n = 20; M±m)

Indicators	Background indicators	Day 1		Day 3		Day 5	
		Control group	Experienced group	Control group	Experienced group	Control group	Experienced group
ALAT, Units/l	63.5±3.2	60.1±3.0	63.2±3.16	64.2±3.21	69.8±3.49	67.3±2.87	75.6±3.78
ASAT, Units/l	80.1±4.01	85.0±4.75	88.7±4.44	88.2±4.4	92.9±3.8	82.6±4.13	94.4±4.7
GGT, Units/l	5.71±0.3	5.2±0.21	6.11±0.31	5.89±0.29	6.5±0.33	5.13±0.26	6.9±0.35
Amylase, Units/l	203.9±10.2	203.2±10.2	185.1±9.24	201.5±9.58	199.0±9.45	213.4±9.67	234.5 ±9.63
Alkaline phosphatase, Units/l	8.1±0.41	8.3±0.42	18.5±0.93	7.46±0.37	22.1±1.11	8.77±0.44	28.8±1.44
Creatinine, μmol/l	180.3±9.0	170.0±8.85	181.5±9.1	195.2±9.76	208.3±10.3	183.4±9.2	197.2±9.9
Urea, mmol/l	6.7±0.34	6.9±0.35	9.7±0.5	7.1±0.36	10.5±0.53	6.41±0.32	10.9±0.55
Cholesterol, mmol/l	1.0±0.06	0.9±0.05	1.4±0.07	1.1±0.06	1.6±0.08	1.2±0.03	1.3±0.06
Glucose, mmol/l	5.5±0.28	5.42±0.27	6.2±0.31	5.65±0.28	5.9±0.25	5.47±0.2	5.31±0.27
Total protein, g/l	63.8±3.2	72.3±3.6	65.4±3.3	67.8±3.39	69.2±3.5	74.3±3.72	72.0±3.6
Albumin, g/l	37.9±2.0	40.2±2.01	48.5±2.43	36.12±1.81	50.6±2.53	33.7±1.69	53.9±2.7

By the end of the experiments, the activity of alanine aminotransferase in the group of clinically healthy animals had not changed considerably, but it had increased by 16% in the group of sick animals.

After the final dose of chloramphenicol was administered to the second group, aspartate aminotransferase activity dropped by 6%.

By the fifth day of the experiment, the activity of gamma-glutamyltransferase had risen in the group of clinically healthy animals and was still within the normal range. This indicator increased by 11% in the ill animal group on the final day of the research, although it stayed within the normal range.

Amylase activity rose by 5% and 21%, respectively, after the final antibiotic dose in the groups of clinically healthy animals and unwell animals. In the group of animals that were clinically healthy, the activity of alkaline phosphatase was within normal bounds, and on the fifth day of the experiment, it grew by 5% and by 36% in the second group. Alkaline phosphatase activity in the ill animals was above normal levels, indicating that the body of the laboratory animals was undergoing an inflammatory process.

During the course of the trial, the serum creatinine content in the group of clinically healthy animals grew by 7%, whereas it increased by 8% in the group of ill animals. By day 5, the amount of urea in the blood serum in the first group had dropped by 7%, whereas it had risen by 11% in the second. The pathology of the vision organ that was caused is what accounts for the elevation in this indicator over the usual range in the group of ill animals. Both the group of animals who were clinically healthy and the group of ill animals had cholesterol levels that were within the normal range. The ill animals' group's cholesterol levels dropped by 7% on the final day of the trial.

While the study was being conducted, the glucose content in the group of animals that were clinically well grew by 1%, while it declined by 14% in the group of sick animals. The total protein content in the group of clinically healthy animals grew by 3% on the fifth day of the trial, while it increased by 9% in the ill animals.

The albumin content did not change much in the group of clinically healthy animals following the final dose of chloramphenicol, but it rose by 10% in the group of ill animals. Because albumin is linked to an inflammatory response in the body, the second group's blood serum albumin level was consistently higher than the normal limit throughout the trial.

The presence of an acute inflammatory process in an animal's body is therefore confirmed by hematological and biochemical signs.

Conclusion

Thus, levomycetin is an effective antibiotic in the treatment of eye infections, which can be used as one of the components of multifactorial therapy. The permeability of the blood-ocular barrier with levomycetin group medications was investigated in this work under both pathological and normal situations. According to the data obtained, the amount of chloramphenicol in the blood serum in both groups throughout the study was within the therapeutic concentration. The minimal therapeutic concentration of chloramphenicol in the intraocular fluid was reached in the group of clinically healthy animals on the fifth day of the experiment and in the group of ill animals on the third day of the investigation.

The second group of animals showed the following changes when the morphological structures of the eye were examined: swollen conjunctival stroma, sclera with inflammatory infiltration phenomena, and signs of interplate edema in the cornea with a violation of the stromal plate parallelism, pronounced inflammatory infiltration, desquamation of the corneal epithelium, significant vasodilation in the iris, iris and ciliary processes with lymphocytic infiltration, signs of uveitis in the vascular membrane, inflammatory infiltration of the retina. As a result, it has been

determined that the micromorphology of the ocular structures in the vascular membrane that forms the histohematic barrier has changed.

The disease of the organ of vision in the second group of animals was verified by the hematological and biochemical examination of blood serum.

Acknowledgments: The authors are thankful to colleagues from Dagestan State Medical University for assistance in experiments.

Conflict of interest: None

Financial support: None

Ethics statement: The protocol for experiments with beetles complied with the requirements of the European Convention for the Protection of Vertebrate Animals used for Experimental and other Scientific Purposes.

References

- Alattas, O. A., Hamdi, A. A., Mudarba, F. M. M., Alshehri, A. M., Al-Yahya, M. S., Almotairi, S. A., Saeed, R. A., Buamer, M. M., Alsuwailem, M. S., & Alamri, I. A. (2019). Red Eye Diagnosis and Management in Primary Health Care. *Archives of Pharmacy Practice*, 10(3), 1-5.
- Alsubaie, A. J. M., Alsaab, S. O., Alshuaylan, R. N., Alosimi, S. H. M., Al-Hasani, H. M., Alqahtani, K. N., Alqahtani, A. S. S., Alsubaiei, N., Boudal, E. K., & Atallah, H. (2021). An Overview on Dry Eye Disease Evaluation and Management Approach in Primary Health Care Centre. *Archives of Pharmacy Practice*, 12(4), 58-64.
- Blinov, A. V., Kachanov, M. D., Gvozdenko, A. A., Nagdalian, A. A., Blinova, A. A., Rekhman, Z. A., Golik, A. B., Vakalov, D. S., Maglakelidze, D. G., Nagapetova, A. G., et al. (2023). Synthesis and Characterization of Zinc Oxide Nanoparticles Stabilized with Biopolymers for Application in Wound-Healing Mixed Gels. *Gels*, 9(1), 57. doi:10.3390/gels9010057
- Blinov, A. V., Nagdalian, A. A., Povetkin, S. N., Gvozdenko, A. A., Verevkina, M. N., Rzhepakovsky, I. V., Lopteva, M. S., Maglakelidze, D. G., Kataeva, T. S., Blinova, A. A., et al. (2022). Surface-oxidized polymer-stabilized silver nanoparticles as a covering component of suture materials. *Micromachines*, 13(7), 1105. doi:10.3390/mi13071105
- Coca-Prados, M. (2014). The blood-aqueous barrier in health and disease. *Journal of Glaucoma*, 23, S36-S38. doi:10.1097/IJG.0000000000000107
- Cronau, H., Kankanala, R. R., & Mauger, T. (2010). Diagnosis and management of red eye in primary care. *American Family Physician*, 81(2), 137-144.
- Darougar, S., Viswalingam, M., Treharne, J. D., Kinnison, J. R., & Jones, B. R. (1977). Treatment of TRIC infection of the eye with rifampicin or chloramphenicol. *British Journal of Ophthalmology*, 61(4), 255-259. doi:10.1136/bjo.61.4.255

- Dhyani, A., & Kumar, G. (2019). A new vision to eye: Novel ocular drug delivery system. *Pharmacophore*, *10*(1), 13-20.
- Galland, F., Seady, M., Taday, J., Smaili, S. S., Gonçalves, C. A., & Leite, M. C. (2019). Astrocyte culture models: Molecular and function characterization of primary culture, immortalized astrocytes and C6 glioma cells. *Neurochemistry International*, *131*, 104538. doi:10.1016/j.neuint.2019.104538
- Garner, W. H., Scheib, S., Berkowitz, B. A., Suzuki, M., Wilson, C. A., & Graff, G. (2001). The effect of partial vitrectomy on blood-ocular barrier function in the rabbit. *Current Eye Research*, *23*(5), 372-381. doi:10.1076/ceyr.23.5.372.5439
- Iosseliani, D. G., Boshia, N. S., Sandodze, T. S., Azarov, A. V., & Semitko, S. P. (2020). The effect of revascularization of the internal Carotid artery on the Microcirculation of the eye. *Journal of Advanced Pharmacy Education & Research*, *10*(2), 209-214.
- Jordán, J., & Ruíz-Moreno, J. M. (2013). Advances in the understanding of retinal drug disposition and the role of blood-ocular barrier transporters. *Expert Opinion on Drug Metabolism & Toxicology*, *9*(9), 1181-1192. doi:10.1517/17425255.2013.796928
- Kaneko, T., Kodani, E., Fujii, H., Asai, R., Seki, M., Nakazato, R., Nakamura, H., Sasabe, H., & Tamura, Y. (2021). Anemia and atrial fibrillation as independent risk factors for new-onset chronic kidney disease: the TAMA-MED Project—CKD and AF. *Clinical Kidney Journal*, *14*(10), 2221-2226. doi:10.1093/ckj/sfab014
- Lam, R. F., Lai, J. S. M., Ng, J. S. K., Rao, S. K., Law, R. W. K., & Lam, D. S. C. (2002). Topical chloramphenicol for eye infections. *Hong Kong Medical Journal*, *8*(1), 44-47.
- Liu, P., Thomson, B. R., Khalatyan, N., Feng, L., Liu, X., Savas, J. N., Quaggin, S. E., & Jin, J. (2018). Selective permeability of mouse blood-aqueous barrier as determined by ¹⁵N-heavy isotope tracing and mass spectrometry. *Proceedings of the National Academy of Sciences*, *115*(36), 9032-9037. doi:10.1073/pnas.1807982115
- Lublinsky, S., Major, S., Kola, V., Horst, V., Santos, E., Platz, J., Sakowitz, O., Scheel, M., Dohmen, C., Graf, R., et al. (2019). Early blood-brain barrier dysfunction predicts neurological outcome following aneurysmal subarachnoid hemorrhage. *EBioMedicine*, *43*, 460-472. doi:10.1016/j.ebiom.2019.04.054
- Lyashenko, E. N., Uzbekova, L. D., Polovinkina, V. V., Dorofeeva, A. K., Ibragimov, S. U. S. U., Tatamov, A. A., Avkaeva, A. G., Mikhailova, A. A., Tuaeava, I. S., Esiev, R. K., et al. (2023). Study of the Embryonic Toxicity of TiO₂ and ZrO₂ Nanoparticles. *Micromachines*, *14*(2), 363. doi:10.3390/mi14020363
- Mezhidov, B. S., Belyaeva, A. A., Kh, S. M., Bimarzaev, S., Bektashev, A., Shekhshebekova, A. M., & Dzgoeva, M. G., (2021). Prospects for creating 3D models of internal organs based on computer and magnetic resonance imaging images in emergency surgery and resuscitation. *Pharmacophore*, *11*(1), 8-14. doi:10.51847/3TLcii4n42
- Ramadan, M., Mohammad, B., Karim Hussein, A. N., & Ahmed, A. (2019). The effect of long term treatment with betablockers in increasing the incidence of bradycardia in patients undergoing posterior segment eye surgeries. *Journal of Advanced Pharmacy Education & Research*, *9*(3), 13-16.
- Rushford, W. A. I., Holman, R. M., & Pulvertaft, T. B. (1978). Tanderil®/Chloramphenicol Eye Ointment in the Treatment of the “Red Eye” Seen in General Practice. *Journal of International Medical Research*, *6*(2), 141-143. doi:10.1177/030006057800600213
- Schoeneberger, V., Eberhardt, S., Menghesha, L., Enders, P., Cursiefen, C., & Schaub, F. (2023). Association between blood-aqueous barrier disruption and extent of retinal detachment. *European Journal of Ophthalmology*, *33*(1), 421-427. doi:10.1177/11206721221099251
- Shevchenko, Y. S., Plohova, D. P., Bulakhova, I. N., Mishvelov, A. E., Kubalova, M. E., Badriev, G. B., Mildzikhov, K. A., Simonov, A. N., Verevkina, M. N., Okolelova, A. I., et al. (2020). Experience of carrying out magnetic resonance imaging with the use of specialized protocols and programs computer post-processing. *Pharmacophore*, *11*(2), 77-81.
- Shmyreva, V. F., Slu, P., Novikov, I. A., & IuS, Z. (2005). Methods of digital differential fluorescein study of the ocular drainage tract. *Vestnik Oftalmologii*, *121*(3), 3-5.
- Smith, A. L., & Weber, A. (1983). Pharmacology of chloramphenicol. *Pediatric Clinics of North America*, *30*(1), 209-236. doi:10.1016/s0031-3955(16)34330-9
- Tomi, M., & Hosoya, K. I. (2010). The role of blood-ocular barrier transporters in retinal drug disposition: an overview. *Expert Opinion on Drug Metabolism & Toxicology*, *6*(9), 1111-1124. doi:10.1517/17425255.2010.486401
- Valori, C. F., Guidotti, G., Brambilla, L., & Rossi, D. (2019). Astrocytes: emerging therapeutic targets in neurological disorders. *Trends in Molecular Medicine*, *25*(9), 750-759. doi:10.1016/j.molmed.2019.04.010
- Zmyslowska, A., Waszczykowska, A., Baranska, D., Stawiski, K., Borowiec, M., Jurowski, P., Fendler, W., & Mlynarski, W. (2019). Optical coherence tomography and magnetic resonance imaging visual pathway evaluation in Wolfram syndrome. *Developmental Medicine & Child Neurology*, *61*(3), 359-365. doi:10.1111/dmcn.14040