

The Preventive and Restorative Potentials of Shilajit Extract in Rats Treated with Mercury Chloride

Dalia Mostafa Mohammed Domiaty*

Received: 17 June 2022 / Received in revised form: 12 September 2022, Accepted: 17 September 2022, Published online: 20 September 2022
© Biochemical Technology Society 2014-2022
© Sevas Educational Society 2008

Abstract

There has been a growing interest in the use of Shilajit powder as an adjuvant for the treatment of various ailments. This study sought to evaluate the preventive and restorative potentials of Shilajit in a model of spleen toxicity induced by mercury chloride in rats and its effects on the MLH1 gene expression. Four groups of twenty male Wistar rats (n=5) were created at random. Group, I was the untreated control group. Group II was given an intraperitoneal (IP) dose of HgCl₂ at 1mg/kg body weight for 3 weeks. Group III was given an oral dose of Shilajit extract (500 mg/ kg b.w) daily for 3 weeks and then HgCl₂ at a dose of 1 mg/kg b.w /IP daily for 3 weeks. Group IV received an oral dose of 500 mg/kg body weight of Shilajit extract for 3 weeks after receiving an IP dose of HgCl₂ at 1 mg/kg body weight for 3 weeks. Bodyweight, relative spleen weight, hematological parameters, tissue oxidative stress, the expression of the MLH1 gene, and spleen histology were evaluated. The results showed that HgCl₂ administration to rats altered the hematological parameters and spleen histology in addition to leading to a decrease in the spleen's GSH content and an increase in lipid peroxidation. However, the oral administration of Shilajit in the preventive model showed more potency in preventing the toxicity caused by HgCl₂ exposure. Therefore, more research is required to clarify the restorative potentials of Shilajit on HgCl₂-induced spleen toxicity.

Keywords: Medicinal plant, Oxidative stress, Reactive oxygen species, Gene expression, Genomic instability

Introduction

The spleen is the body's largest lymphoid organ. It is a part of the reticuloendothelial system. It is located in the left hypochondria region of the abdomen. As a vascular organ, the spleen helps in regulating the volume of circulating blood, filtration of the blood against blood-borne pathogens, production of white blood cells, and synthesis of antibodies. It also plays a role in iron metabolism and the homeostasis of red blood cells (Chelladurai *et al.*, 2019; Xing *et al.*, 2019).

Spleen toxicity can occur as a result of exposure to a large concentration of harmful substances through food, water,

environment, and drugs (Xing *et al.*, 2019), causing hyperplasia, splenomegaly, mesenchymal tumors, highly malignant soft tissue, and sarcoma (Makhdoumi *et al.*, 2019). These insults to the spleen arise as a result of erythrocyte damage and oxidative damage to DNA, lipids, and proteins (Makhdoumi *et al.*, 2019). The modification of proteins caused by oxidation can make them more sensitive and lead to proteolytic degradation which can result in the abnormal function of the spleen (Ping *et al.*, 2020).

Mercury is one of the most toxic metal elements on earth which causes environmental pollution. It occurs in different forms including organomercury, elemental mercury, and inorganic compounds (Elsagh *et al.*, 2021). Mercury Chloride (HgCl₂) is an inorganic mercury salt and is one of the most toxic forms of mercury available. It is corrosive and highly soluble and exposure to this salt is usually through ingestion via water and food. Once exposed to HgCl₂, this compound accumulates in different organs causing toxicity and resulting in oxidative stress, apoptosis, and inflammation (Officioso *et al.*, 2018; Nabil *et al.*, 2020).

Shilajit is a brown-blackish powder usually exuded from high mountain rocks mostly in the Himalayas. The powder exudates are prevalent in India and Nepal where the Himalayan mountains are situated but they can also be found in Northern Chile, Russian, Tibet, and Afghanistan (Ojha *et al.*, 2021). For centuries, Shilajit has been used by Ayurvedic medicine for its rejuvenating and anti-aging properties. The major component of Shilajit includes humic acid, humic and fulvic acids (Jacob *i.*, 2019). Studies have also shown that Shilajit contains some amount of ellagic acid, albumins, triterpenes fatty acids, gums, and aromatic carboxylic acids. Some pharmacological activities that have been linked to Shilajit include anti-inflammatory activity, antidiabetic analgesic, spermatogenic and orogenic, anti-fungal, radioprotective, anti-oxidant, immunomodulatory, and anti-viral properties (Mishra *et al.*, 2019; Ezhilarasi *et al.*, 2020).

MLH1 (mutL homolog 1) is a gene that functions in the provision of instruction for the synthesis of the proteins involved in the repair of damaged genes. It is a mismatch repair gene and coordinates the activities of genes in the repair of mismatch mutations. This gene helps in the prevention of cancer development (Kamiza *et al.*, 2018). An earlier investigation into the molecular basis of aniline-induced spleen toxicity found that tumor growth may be induced by an increase in the phosphorylation of the pRB protein and expression of cyclin-dependent kinases and cyclins which is followed by an increase in the cell cycle regulatory protein cyclins and a decrease in CDK inhibitors. This can increase the expression

Dalia Mostafa Mohammed Domiaty *

Department of Biology, College of Science, University of Jeddah, Jeddah, Saudi Arabia.

*E-mail: ddomiaty@uj.edu.sa



of DNA excision repair and mismatch repair genes to prevent tumor and cancer formation (Makhdoumi *et al.*, 2019). Hence, this study aimed to explore the preventive and ameliorative properties of Shilajit in a model of spleen toxicity induced by mercury chloride in rats and its effects on MLH1 gene expression.

Materials and Methods

Plant Material and Preparation of Extract

The Shilajit power was obtained from an herbal and folk medicine market in Jeddah, Saudi Arabia, and the extract was prepared according to the method of (Ghasemkhani *et al.*, 2021) with a slight modification. Briefly, after the dissolution of 80g of Shilajit power in boiling water at 100° C, the Shilajit extract was then placed in an incubator at 70° C for 30 hours for drying. Shilajit extract was then mixed with PBS and then filtered via a 0.2-mm filter, concentrated to 8.5 mg/ml of Shilajit extract, and kept till usage at 4 °C.

Animals

Male Wistar rats weighing 150-250 g were purchased from the King Fahd Medical Research Center, King Abdulaziz University, Jeddah, Saudi Arabia. Animals were left to acclimatize to the lab ambiance for one week (12hr/12hr light off/on) and fed on a lab animal diet with freely available water. The King Abdulaziz University College of Medicine's Bioethics Committee approved this animal experiment with No. HAP-02-J-094.

Chemicals

Mercury chloride (HgCl₂) was purchased from Sigma-Aldrich, (Missouri, United States). All other chemicals were of analytical grade.

Experimental Design

Rats were randomly placed into four groups (n = 5) after acclimatization and given the following treatment:

Group I (Control): the control group, received no treatment. **Group II (HgCl₂):** This group received HgCl₂ intraperitoneally (IP) at a dose of 1mg/kg body weight (b.w.) for 3 weeks. **Group III (Preventive group; Shilajit + HgCl₂):** Animals in this group received Shilajit extract orally at a dose of (500 mg/ kg b.w) daily/ 3 weeks and then HgCl₂ at a dose of 1 mg/kg b.w /IP daily for 3 weeks. **Group IV (Restorative group; HgCl₂ + Shilajit):** This group received an IP of HgCl₂ at a dose of 1 mg/kg b.w for 3 weeks followed by a daily oral dose of (500 mg/ kg b.w) of Shilajit extract for 3 weeks.

After the three weeks of experimental periods, food was withdrawn from the animals overnight and they were later euthanized under diethyl ether anesthesia. Following this, blood was drawn from the animals and the spleen was removed, rinsed in normal saline, and weighed. Part of the spleen was either stored in 10% buffered formalin for histological analysis or kept at -80°C for extraction of RNA. The leftover spleen tissue was blended in a 100 mM phosphate buffer with a pH of 7.4 at 14,000 rpm for 30 min.

Evaluation of Hematological Parameters

Using a Cobas m 511 integrated hematology analyzer, the hematocrit, white blood cell count, hemoglobin, and red blood cell count were measured in animal blood samples that were obtained in EDTA-containing tubes.

Evaluation of Spleen Antioxidant Level

The levels of catalase (CAT) in the spleen tissues were measured in the supernatant obtained following the centrifugation at 14,000 rpm using a commercial kit (MyBioSource, California, USA), according to the manufacturer's instructions.

Evaluation of Oxidative Stress Biomarkers

For this, the supplier's instructions were followed when measuring the amounts of glutathione (GSH) and malondialdehyde (MDA) in the supernatant collected after centrifugation at 14,000 rpm using a commercial kit (MyBioSource, California, USA).

RNA Extraction and Real-time Quantitative PCR (RT-qPCR)

According to the supplier's recommendations, total RNA was extracted from the spleen using a (Qiagen RNeasy mini kit, cat # 74104). Next, 200ng of the extracted RNA was used in cDNA synthesis by the use of the M-MLV Reverse Transcriptase System (Promega, USA), and the qPCR reaction was made up of the following components: cDNA, 3 mL; right and left primers (**Table 1**), 0.5 mL (500 nM); purified water, 1 mL; SYBR Green Master Mix (Applied Biosystems, USA). To assess the relative mRNA expression of the MLH1 gene, the 2^{-ΔΔCT} method was applied and normalized to the expression of GAPDH.

Table 1. Primer sequences

Primers	Primers sequence (5'-3')
MLH1 - left	5'-GTGCTGGCAATCAAGGGACCC-3'
MLH1 - right	5'-CACGGTTGAGGCAATGGGTAG-3'
GAPDH - left	5'-GAT GGT GAA GGT CGG TGT G-3'
GAPDH -right	5'-ATG AAG GGG TCG TTG ATG G-3'

Histopathological Studies

The fixation of spleen tissue was carried out in 10% buffered formalin, then embedded in paraffin wax after being dried out graded ethanol for a day at room temperature. To evaluate histopathological alterations, hematoxylin, and eosin (H&E) were used to stain the sections of tissue blocks that were cut into thin sections. Light microscope images of stained spleen sections were taken at 400x magnification.

Statistical Analysis

The statistical analyses for this study were conducted using one-way ANOVA, and the data are presented as mean SEM. Dunnett's multiple comparisons test was used to compare means, and a significance level of p less than 0.05 was chosen.

Results and Discussion

Effects of HgCl₂ and Shilajit on Final Body Weight and Relative Spleen Weight

When compared to the untreated control rats and the preventative groups, the administration of HgCl₂ to rats caused a significant reduction in body weight in each case. However, body weight does not differ between the groups treated with HgCl₂ and the restorative group (Figure 1a). In addition, the administration of HgCl₂ to rats led to a decrease in the relative spleen weight in comparison to the untreated animals in the control group. Animals in both the preventative group and the restorative group showed a significant reduction in the relative spleen weight when compared to the rats administered with only HgCl₂ (Figure 1b).

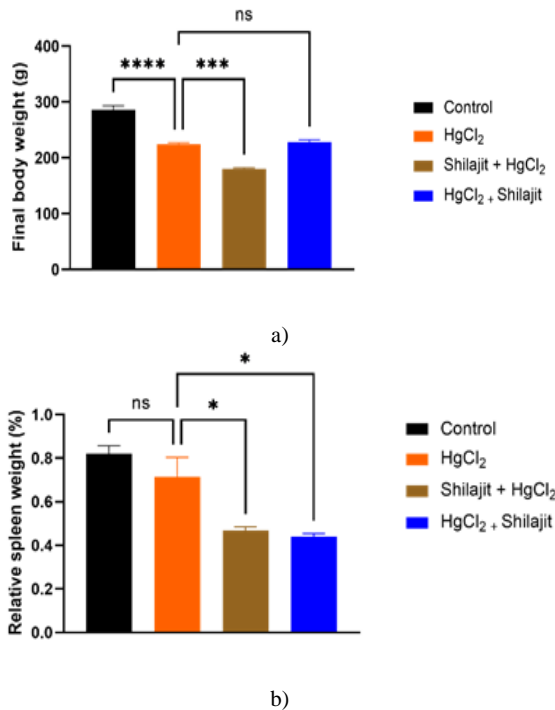


Figure 1. Effects of HgCl₂ and Shilajit on final body weight and relative spleen weight. a) final body weight. b) relative spleen weight

Effects of HgCl₂ and Shilajit on Hematological Parameters

As shown in Figure 2a, compared to rats in the control group ($p < 0.001$) and the preventative group ($p < 0.1$) respectively, animals given HgCl₂ had significantly higher white blood cell counts. When compared to HgCl₂-treated rats, rats in the restorative showed a considerable decrease in white blood cells and this decline was near normal (Figure 2a). Additionally, when compared to the rats in the untreated control group, the RBC count in the HgCl₂-only treated rats significantly decreased. Rats in the preventative group recorded an increase in the RBC counts when compared to rats administered with only HgCl₂. However, there was no discernible distinction in the RBC counts between the animals in the restorative group and the HgCl₂-only treated rats (Figure 2b). A similar result was obtained with the Hemoglobin and hematocrit concentrations (Figures 2c and 2d).

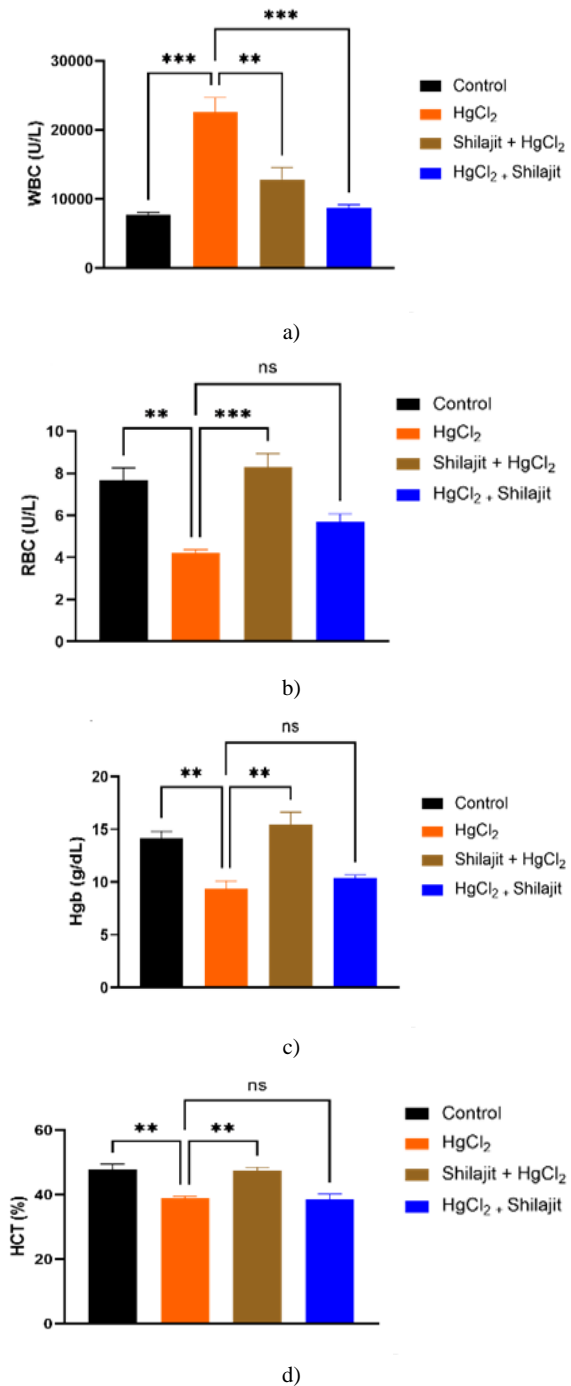


Figure 2. Effects of HgCl₂ and Shilajit on blood parameters. a) White blood cell counts, b) Red blood cell counts, c) Hemoglobin concentration, d) Hematocrit concentration

Effects of HgCl₂ and Shilajit on Tissue Antioxidant, Non-Antioxidant Content, and MLH 1 Gene Expression Level

The treatment of rats with HgCl₂ did not result in a noticeable change in the catalase activity in the spleen when compared to untreated animals in the control group. A similar result was obtained in the CAT activity in the spleen of rats in the restorative

group. However, when compared to the HgCl_2 -administered rats, those in the preventative group displayed a significantly higher level of CAT activity (**Figure 3a**). In addition, when compared to the untreated animals in the control group, the GSH contents in the spleen of the rats administered with HgCl_2 dramatically decreased ($p < 0.001$) (**Figure 3b**). When compared to rats administered with HgCl_2 , the preventative group's rats displayed a significantly higher level of spleen GSH (**Figure 3b**). Furthermore, rats administered with HgCl_2 presented a significant elevation in the Spleen's MDA content, thus signifying an increase in the peroxidation of the membrane of the spleen. Rats in both the preventive and restorative groups, however, showed no difference in the MDA content when compared to the HgCl_2 -only treated rats (**Figure 3c**). Similarly, rats treated with HgCl_2 showed a significant upregulation of the MLH 1 gene expression when compared with the untreated animals in the control group. Interestingly, both the rats in the preventive and restorative groups, showed significant downregulation of the MLH 1 gene when compared to the HgCl_2 -only treated rats (3d).

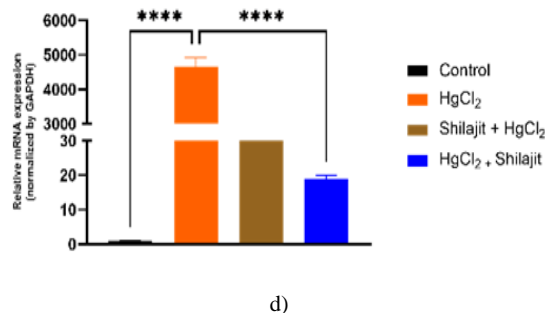
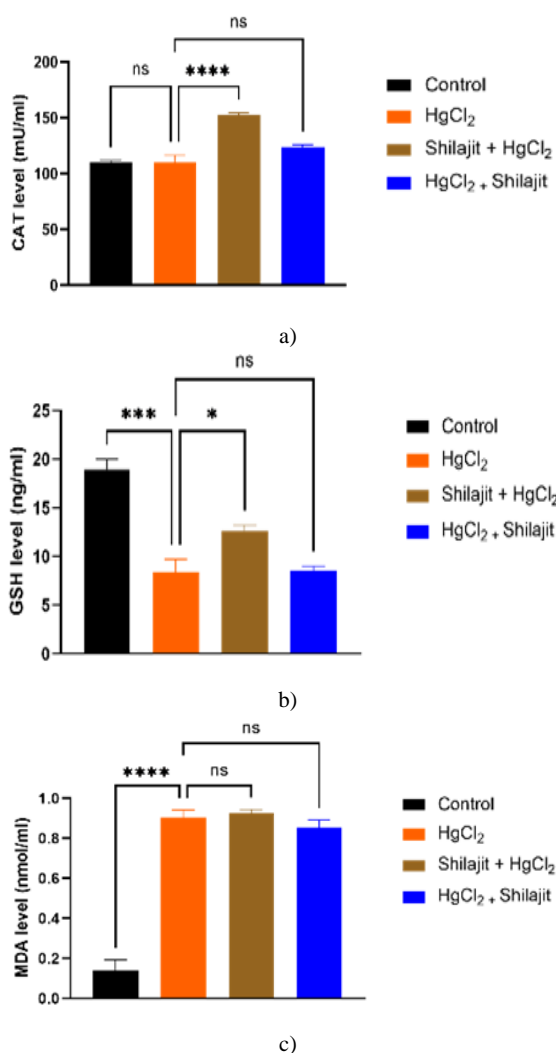
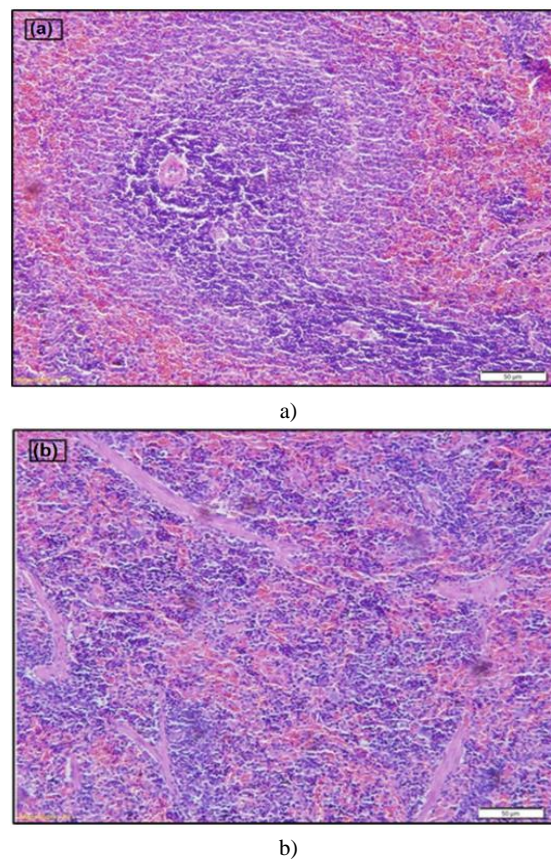
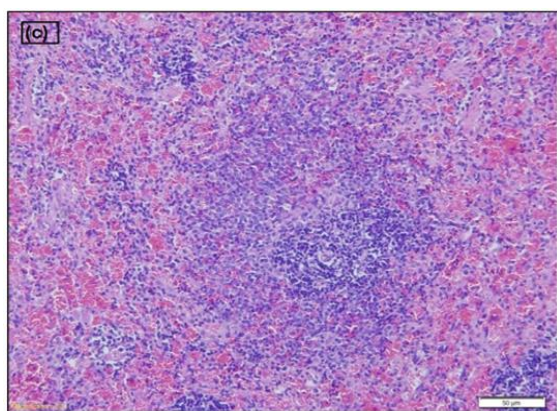


Figure 3. Effects of HgCl_2 and Shilajit on tissue antioxidant, non-antioxidant content, and MLH gene expression level. a) Catalase activity, b) GSH content, c) MDA level, d) Relative MLH 1 gene expression

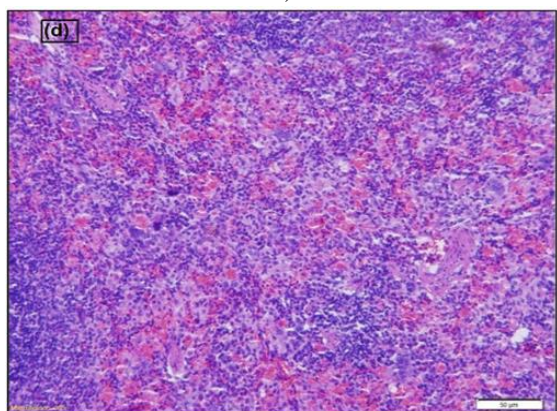
Effects of HgCl_2 and Shilajit on Spleen Histological

As shown in **Figure 4** below, rats in the control group showed normal spleen histology with well-separated red and white pith in addition to well-arranged lymphocytes (**Figure 4a**). However, animals administered with HgCl_2 showed necrosis, inflammatory cells disrupted lymphocytes, and disorganized red and white paths (**Figure 4a**). Intriguing, animals in the preventive and restorative groups showed an improvement in the spleen histoarchitecture (**Figure 4**).





c)



d)

Figure 4. Effects of HgCl₂ and Shilajit on the histological appearance of the Spleen. a) Spleen's histological section from the untreated control group demonstrates normal spleen architecture. b) The section of the spleen from animals administered with HgCl₂ showed necrosis, inflammatory cells, disrupted lymphocytes, and a disorganized red-and-white path. necrosis and macrophage infiltration. c) Spleen histology of the animals in the preventive group showed an improvement in the spleen architecture. d) Spleen histology of the animals in the restorative group showed an improvement in the spleen architecture

The increase in human industrial activities has increased by harmful chemicals. This has led to the pollution and contamination of the environment with dangerous chemicals posing a serious threat to human health and other animals. Mercury Chloride is a known toxic compound that causes damage to organs such as the spleen, the liver, the kidney, and the nervous system (Fan *et al.*, 2020). This salt damages these organs by inducing oxidative stress and causing apoptosis (Li *et al.*, 2019).

The purpose of this research was to ascertain whether Shilajit could prevent or reduce mercury chloride-induced spleen toxicity. The results revealed that the test group's final body weight was significantly reduced as a result of the HgCl₂ administration. Jahan *et al* also showed that HgCl₂ administration to the test subjects led to a reduction in their final body weight. However, the inorganic salt did not affect the organ weight (Jahan *et al.*, 2019). Interestingly, although Shilajit did not increase the body weight, it

caused a significant reduction in the spleen weight when it was used as both a preventive and restorative model.

White blood cells (WBCs) are immune cells that are crucial in the development of serious illnesses like cancer, infections, and inflammatory conditions (Wang *et al.*, 2022). An increase in the levels of the WBCs signifies the body's reaction to cell damage and infection (Wirth *et al.*, 2018). The results of this study showed that the administration of HgCl₂ resulted in a considerable increase in white blood cell count. is likely to be due to inflammation arising from the body's response to infection or exposure to toxic materials (Kabat *et al.*, 2017). The results of this study also showed that HgCl₂ significantly reduced the levels of hemoglobin, hematocrit, and red blood cell count when compared to the other groups. The red blood cells and hemoglobin help in the transportation of oxygen and carbon dioxide from the lungs to the tissue and vice versa, and help in the maintenance of the systemic acid/base level (Kuhn *et al.*, 2017). Hematocrit is used to determine the volume percentage of red blood cells (RBCs) in total blood (Kishimoto *et al.*, 2020). A low RBC count and hemoglobin level could cause endothelial dysfunction which could result in anemia (Kuhn *et al.*, 2017). The hematocrit level is also used as a parameter for the diagnosis of anemia and cardiovascular disease since a low hematocrit level means a low RBC count (Malenica *et al.*, 2017).

Catalase is an enzyme that protects the body from oxidative stress by breaking down hydrogen peroxide molecules into water and oxygen. An increase in CAT levels signifies a response to the presence of oxidative species (Nandi *et al.*, 2019). The results of this study showed a significant elevation of catalase in the preventive group (Figure 3a). However, a decrease in the catalase concentration could result in a variety of age-related degenerative diseases like Parkinson's disease, bipolar disorder, and diabetes (Nandi *et al.*, 2019). The decrease and increase in the GSH and MDA levels induced by HgCl₂ exposure respectively showed HgCl₂-induced oxidative stress. The same observation was recorded by Fan *et al.* during their study on mercury chloride-induced toxicity in chicken (Fan *et al.*, 2020). This decrease in GSH concentration could lead to chronic age-related diseases like Alzheimer's disease and the increase in its concentration could help in the prevention of oxidative stress and increase the level of total antioxidant capacity (Braidly *et al.*, 2019).

Furthermore, an increase in the MDA level can cause oxidative damage to the affected organs like the brain and spleen (Hurşitoğlu *et al.*, 2021). Malondialdehyde (MDA) is an end product of the peroxidation of the cell. An increase in free radical levels results in the overproduction of MDA and hence serves as a marker for oxidative stress and the antioxidant status of cancer patients (Mao *et al.*, 2019). The results obtained herein were similar to that of Nabil *et al.* who worked on the preventive effect of DPPD against mercury chloride-induced hepatorenal damage (Nabil *et al.*, 2020). In this study, it was also observed that exposure of rats to mercury chloride caused a significant upregulation of the MLH1 gene expression. The MLH1 gene is a DNA mismatch repair gene. In prostate cancer patients, Wilczak *et al.* found that its overexpression coincides with the emergence of genetic instability and is associated with tumor aggressivity and early PSA recurrence

(Wilczak *et al.*, 2017). The results here showed the significant downregulation of the MLH 1 gene expression in both the preventive and restorative groups. This could likely be due to Shilajit's ability to stabilize the spleen's DNA and prevent the induction of apoptosis.

The histological examination of the spleen tissue showed that the exposure of rats to HgCl₂ caused cell deaths (necrosis), and inflammation, and led to the distortion of the lymphocytes, the red and white piths. A similar observation was noted in mercury induced-toxicity in the chicken spleen (Fan *et al.*, 2020). However, all these changes caused by the HgCl₂ exposure were ameliorated when Shilajit was administered as a preventive and restorative measure and complements the observation recorded with the downregulation of the MLH 1 gene expression in both groups.

Conclusion

In this study, we explored the preventive and restorative potentials of Shilajit against HgCl₂-induced spleen toxicity in rats and examined its effect on the expression of the MLH 1 gene. The results here showed that rats administered with HgCl₂ showed a noticeable change in their body weight. In addition, the administration of HgCl₂ to rats resulted in a decline in the hematocrit, hemoglobin, red blood cell counts, and spleen GSH level and changed the spleen histology. Furthermore, the treatment of rats with HgCl₂ led to an increase in white blood cell counts, lipid peroxidation, and an increase in the expression of the MLH1 gene. Intriguingly, the oral administration of Shilajit in the preventive model showed more potency in ameliorating the toxicity caused by HgCl₂ administration. Therefore, more research is required to clarify the restorative potentials of Shilajit on HgCl₂-induced spleen toxicity.

Acknowledgments: None

Conflict of interest: None

Financial support: None

Ethics statement: A declaration by the Bioethics Committee of Scientific and Medical Research approved this animal experiment with No. HAP-02-J-094.

References

Braidy, N., Zarka, M., Jugder, B. E., Welch, J., Jayasena, T., Chan, D. K. Y., Sachdev, P., & Bridge, W. (2019). The Precursor to Glutathione (GSH), γ -Glutamylcysteine (GGC), Can Ameliorate Oxidative Damage and Neuroinflammation Induced by A β 40 Oligomers in Human Astrocytes. *Frontiers in Aging Neuroscience*, *11*, 177.

Chelladurai, M., Jacinth, J., Ramamani, T., & Subbulakshmi, G. (2019). Morphological study of spleen and variations in south Indian population. *International Journal of Anatomy and Research*, *7*, 6663-6667.

Elsagh, A., Jalilian, H., & Aslshabestari, M. G. (2021). Evaluation of heavy metal pollution in coastal sediments of Bandar Abbas, the Persian Gulf, Iran: Mercury pollution and

environmental geochemical indices. *Marine Pollution Bulletin*, *167*, 112314.

Ezhilarasi, S. S. V., Kothandaraman, R., Nesamani, R., Balasubramanian, S., & Mahalaxmi, S. (2020). In vitro assessment of cytotoxicity and anti-inflammatory properties of shilajit nutraceutical: A preliminary study. *Journal of Interdisciplinary Dentistry*, *10*(1), 24.

Fan, R. F., Liu, J. X., Yan, Y. X., Wang, L., & Wang, Z. Y. (2020). Selenium relieves oxidative stress, inflammation, and apoptosis within spleen of chicken exposed to mercuric chloride. *Poultry Science*, *99*(11), 5430-5439.

Ghasemkhani, N., Tabrizi, A. S., Namazi, F., & Nazifi, S. (2021). Treatment effects of Shilajit on aspirin-induced gastric lesions in rats. *Physiological Reports*, *9*(7), e14822.

Hurşitoğlu, O., Orhan, F. Ö., Kurutaş, E. B., Doğaner, A., Durmuş, H. T., & Kopar, H. (2021). Diagnostic performance of increased malondialdehyde level and oxidative stress in patients with schizophrenia. *Archives of Neuropsychiatry*, *58*(3), 184-188.

Jacob, K. K., Prashob, P. K. J., & Chandramohanakumar, N. (2019). Humic substances as a potent biomaterials for therapeutic and drug delivery system—a review. *International Journal of Applied Pharmaceutics*, *11*, 1-4.

Jahan, S., Azad, T., Ayub, A., Ullah, A., Afsar, T., Almajwal, A., & Razak, S. (2019). Ameliorating potency of Chenopodium album Linn. and vitamin C against mercuric chloride-induced oxidative stress in testes of Sprague Dawley rats. *Environmental Health and Preventive Medicine*, *24*(1), 1-13.

Kabat, G. C., Kim, M. Y., Manson, J. E., Lessin, L., Lin, J., Wassertheil-Smoller, S., & Rohan, T. E. (2017). White blood cell count and total and cause-specific mortality in the Women's Health Initiative. *American Journal of Epidemiology*, *186*(1), 63-72.

Kamiza, A. B., Hsieh, L. L., Tang, R., Chien, H. T., Lai, C. H., Chiu, L. L., Lo, T. P., Hung, K. Y., You, J. F., Wang, W. C., et al. (2018). polymorphisms of DNA repair genes are associated with colorectal cancer in patients with Lynch syndrome. *Molecular Genetics & Genomic Medicine*, *6*(4), 533-540.

Kishimoto, S., Maruhashi, T., Kajikawa, M., Matsui, S., Hashimoto, H., Takaeko, Y., Harada, T., Yamaji, T., Han, Y., Kihara, Y., et al. (2020). Hematocrit, hemoglobin, and red blood cells are associated with vascular function and vascular structure in men. *Scientific Reports*, *10*(1), 1-9.

Kuhn, V., Diederich, L., Keller, T. C. S. T., Kramer, C. M., Lückstädt, W., Panknin, C., Suvorava, T., Isakson, B. E., Kelm, M., & Cortese-Krott, M. M. (2017). Red Blood Cell Function and Dysfunction: Redox Regulation, Nitric Oxide Metabolism, Anemia. *Antioxidants & Redox Signaling*, *26*(13), 718-742.

Li, S., Baiyun, R., Lv, Z., Li, J., Han, D., Zhao, W., Yu, L., Deng, N., Liu, Z., & Zhang, Z. (2019). Exploring the kidney hazard of exposure to mercuric chloride in mice: Disorder of mitochondrial dynamics induces oxidative stress and results in apoptosis. *Chemosphere*, *234*, 822-829.

- Makhdoumi, P., Hossini, H., Ashraf, G. M., & Limoe, M. (2019). Molecular Mechanism of Aniline Induced Spleen Toxicity and Neuron Toxicity in Experimental Rat Exposure: A Review. *Current Neuropharmacology*, 17(3), 201-213.
- Malenica, M., Prnjavorac, B., Bego, T., Dujic, T., Semiz, S., Skrbo, S., Gusic, A., Hadzic, A., & Causevic, A. (2017). Effect of Cigarette Smoking on Haematological Parameters in Healthy Population. *Medical Archives*, 71(2), 132-136.
- Mao, C., Yuan, J. Q., Lv, Y. B., Gao, X., Yin, Z. X., Kraus, V. B., Luo, J. S., Chei, C. L., Matchar, D. B., Zeng, Y., et al. (2019). Associations between superoxide dismutase, malondialdehyde and all-cause mortality in older adults: a community-based cohort study. *BMC Geriatrics*, 19(1), 1-9.
- Mishra, T., Dhaliwal, H. S., Singh, K., & Singh, N. (2019). Shilajit (Mumie): Current Status of Biochemical, Therapeutic and Clinical Advances. *Current Nutrition & Food Science*, 15(2), 104-120.
- Nabil, A., Elshemy, M. M., Asem, M., & Gomaa, H. F. (2020). Protective Effect of DPPD on Mercury Chloride-Induced Hepatorenal Toxicity in Rats. *Journal of Toxicology*, 2020, 4127284.
- Nandi, A., Yan, L. J., Jana, C. K., & Das, N. (2019). Role of catalase in oxidative stress-and age-associated degenerative diseases. *Oxidative Medicine And Cellular Longevity*, 2019.
- Officioso, A., Panzella, L., Tortora, F., Alfieri, M. L., Napolitano, A., & Manna, C. (2018). Comparative Analysis of the Effects of Olive Oil Hydroxytyrosol and Its 5-S-Lipoyl Conjugate in Protecting Human Erythrocytes from Mercury Toxicity. *Oxidative Medicine and Cellular Longevity*, 2018, 9042192.
- Ojha, R., Gupta, A. K., Pathak, R., & Pandey, S. K. (2021). Shilajit an elixir of Ayurveda: A literary review of traditional usage as well as modern findings. *International Journal of Applied Research*, 7(8), 323-332.
- Ping, Z., Peng, Y., Lang, H., Xinyong, C., Zhiyi, Z., Xiaocheng, W., Hong, Z., & Liang, S. (2020). Oxidative stress in radiation-induced cardiotoxicity. *Oxidative Medicine and Cellular Longevity*, 2020.
- Wang, D., Wang, S., Zhou, Z., Bai, D., Zhang, Q., Ai, X., Gao, W., & Zhang, L. (2022). White Blood Cell Membrane-Coated Nanoparticles: Recent Development and Medical Applications. *Advanced Healthcare Materials*, 11(7), 2101349.
- Wilczak, W., Rashed, S., Hube-Magg, C., Kluth, M., Simon, R., Büscheck, F., Clauditz, T. S., Grupp, K., Minner, S., Tsourlakis, M. C., et al. (2017). Up-regulation of mismatch repair genes MSH6, PMS2, and MLH1 parallels development of genetic instability and is linked to tumor aggressiveness and early PSA recurrence in prostate cancer. *Carcinogenesis*, 38(1), 19-27.
- Wirth, M. D., Sevoyan, M., Hofseth, L., Shivappa, N., Hurley, T. G., & Hébert, J. R. (2018). The Dietary Inflammatory Index is associated with elevated white blood cell counts in the National Health and Nutrition Examination Survey. *Brain, Behavior, and Immunity*, 69, 296-303.
- Xing, H., Chen, J., Peng, M., Wang, Z., Liu, F., Li, S., & Teng, X. (2019). Identification of signal pathways for immunotoxicity in the spleen of common carp exposed to chlorpyrifos. *Ecotoxicology and Environmental Safety*, 182, 109464.