

External Small Intestine Fistula as a Rare Complication of Total Infralevatory Pelvic Evisceration

Evgeny Aleksandrovich Akhtanin*, Pavel Viktorovich Markov, Aleksander Aleksandrovich Goev, Vladimir Yuryevich Struchkov, Hovhannes Robertovich Arutyunov, Tigran Artashesovich Martirosyan, Komildzhon Usmonovich Shukurov

Received: 07 October 2022 / Received in revised form: 12 December 2022, Accepted: 10 December 2022, Published online: 18 December 2022

Abstract

Due to the improvement of surgical techniques, the number of total pelvic evisceration surgeries is increasing annually. However, the number of postoperative complications remains high and varies between 31.2 and 45.1%. A common complication is the formation of a small intestine fistula. Further postoperative management of patients with the presence of a small intestine fistula is not an easy task. The mortality rate for this complication after total pelvic evisceration reaches 34.4%. The paper presents a clinical case of a patient with an external incomplete unformed small intestine fistula that emerged after performing total infralevatory pelvic evisceration due to local advanced rectal cancer. The article gives a review of the literature data on the problem and a clinical example of the occurrence of complications. The authors provide a detailed description of the patient's medical history. The causes of the fistula and further treatment of the patient, aimed at eliminating the small bowel fistula, are given.

Keywords: Intestinal fistula, Total pelvic evisceration, Postoperative complications, Mortality rate, Patient medical case

Introduction

Total pelvic evisceration (TPE) is a surgical intervention aimed at the complete removal of the pelvic organs with the formation of various variants of urine and intestinal discharge (Carvalho *et al.*, 2023). TPE was performed for the first time for bladder cancer by E. M. Bricker in 1940 (Bricker & Modlin, 1951). Three years later, L.H. Appleby repeated this surgery for the first time with rectal cancer (Appleby, 1950; El-Kordy, *et al.*, 2019; Samara *et al.*, 2020). Later, in 1948, A. Brunschwig performed a TPE for recurrent cervical cancer, and the results of six successful surgeries were published in the Cancer journal. On the territory of the former USSR, Dedkov performed the first TPE for rectal cancer in 1974 (Aglullin *et al.*, 2015).

Every year, the number of TPEs is growing, due to the improvement of surgical techniques, anesthesiological and

resuscitation surgery support, and advancement in the combined therapy of oncological diseases of the pelvic organs. The rapid development of technologies and the wider use of medicinal and radiation treatments have expanded the possibilities of surgical interventions in patients with locally advanced oncological diseases of the pelvic organs. The main indications for performing TPE are currently locally advanced malignant tumors of the uterus, bladder, and rectum.

Currently, when a patient is diagnosed with locally advanced rectal cancer, a combination treatment is indicated, namely, neoadjuvant chemoradiotherapy with further radical surgery. After TPE, postoperative mortality is not high and ranges from 0.5 to 2% (PelvEx Collaborative, 2018; Venchiarutti *et al.*, 2019; Peacock *et al.*, 2020). However, the number of postoperative complications remains high and varies between 31.2 and 45.1% (PelvEx Collaborative, 2019). Most often, the postoperative period is complicated by the occurrence of dynamic intestinal obstruction and the formation of pelvic abscesses with the development of local peritonitis (Platt *et al.*, 2018).

According to the literature, the failure of sutures on the small intestine during the formation of a small intestine conduit for urination with the appearance of small intestine fistulas occurs in 2.6 to 3% (Nielsen *et al.*, 2022). Berman *et al.* published for the first time a 17-year history in the treatment of patients with small intestine fistulas after TPE and the incidence of the postoperative intestine fistula was 3.5% (Berman *et al.*, 1976). Most often, the cause of this complication in the early postoperative period is iatrogenic damage to the small intestine, whereas, in the later postoperative period, the main cause is the recurrence of cancer (Yunoki *et al.*, 2020; Yang *et al.*, 2021).

Further postoperative management of patients with the presence of a small intestine fistula is not an easy task, and the mortality rate for this complication after TPE reaches 34.4% (Nielsen *et al.*, 2022).

We did not find any cases of a long-term pelvic abscess with the release of small intestine contents into the perineum and the formation of an external unformed small intestine fistula complicated by severe dermatitis when analyzing the available literature.

Materials and Methods

Patient K., 56 years old, was admitted on 05.09.2022 to the department of abdominal surgery of the National Medical Research Center (NMITs) of Surgery named after A.V. Vishnevsky (Verma & Pandian, 2022).

Evgeny Aleksandrovich Akhtanin*, Pavel Viktorovich Markov, Aleksander Aleksandrovich Goev, Vladimir Yuryevich Struchkov, Hovhannes Robertovich Arutyunov, Tigran Artashesovich Martirosyan, Komildzhon Usmonovich Shukurov

Department of Abdominal Surgery, National Medical Research Center of Surgery named after A. Vishnevsky of the Ministry of Health of the Russian Federation, Moscow, Russia.

*E-mail: akhtanin.evgenii@mail.ru



At the time of admission, the patient complained of abundant small intestine discharge with an admixture of pus, with a volume of about 1 to 1.5 liters going through soft tissue defects in the perineum (Wąsacz & Chomyszyn-Gajewska, 2022).

It is known from the anamnesis that in May 2019, during a planned colonoscopy, a rectal neoplasm was detected, and a biopsy was performed. According to histological examination, this was an adenocarcinoma of the rectum. After further examination, the patient was diagnosed with local advanced rectal cancer cT4N1M0 with an invasion of the bladder (Sabbahi, 2022).

At the oncological consilium, it was decided to perform the first stage of neoadjuvant chemotherapy according to the oxaliplatin and capecitabine (XELOX) scheme. The patient underwent two courses of treatment in the period from October 2019 to November 2019.

At the end of November, the patient noted acute pains in all parts of the abdomen. He was admitted to a hospital at the place of residence, where, after an additional examination, perforation of the sigmoid colon, and widespread fecal peritonitis were observed. Emergency surgical intervention was performed in the following way: laparotomy, obstructive resection of the sigmoid colon with the formation of a single-stem sigmoidostoma, and drainage of the abdominal cavity. On the 9th day of the postoperative period, the patient was discharged in satisfactory condition.

14 days after the surgery, he began to notice periodic vomiting of eaten food and was admitted to a hospital, where, after an examination, multiple abscesses of the abdominal cavity were observed. A relaparotomy was performed, and during the revision of the abdominal cavity, a site of necrosis of the loop of the small intestine was observed. Resection of the loop of the small intestine with the formation of duodenojejunostomosis, sanitation, and drainage of the abdominal cavity was performed. The postoperative period proceeded smoothly, and the patient was discharged in satisfactory condition (Ajwa *et al.*, 2022; Al-Sunbul *et al.*, 2022; Shetty *et al.*, 2022; Zahid *et al.*, 2022).

In the future, the patient underwent a second oncological consilium, where a decision was made to perform a radical surgical intervention in the form of TPE. In March 2020, he underwent surgery in the following volume: infraleatory TPE with Bricker bladder plastic surgery, colostomy, and drainage of the abdominal cavity. The early postoperative period was complicated by the occurrence of a drained pelvic abscess. Up to 2 liters of pus were discharged from the abscess cavity by drainage. The patient was discharged in June 2020 with drainage from the perineum under the outpatient supervision of a surgeon at the place of residence. By the time of discharge, up to 30 ml of pus was discharged by drainage per day. At the end of June, the drainage fell out on its own. After that, the patient dressed the wound himself. In July 2022, he noted the presence of intestinal discharge in the perineum with a tendency to increase (Chidambaranathan & Culathur, 2022)

According to the multislice spiral computed tomography (MSCT) of the abdominal cavity organs with intravenous bolus contrast enhancement, an external unformed incomplete small intestine fistula with the formation of a pelvic abscess was observed.

The general condition upon admission: moderate severity. The abdomen is not swollen, symmetrical, and participates in the act of breathing. The postoperative scar has no signs of inflammation. An external complete colonic fistula (terminal descendostoma) has been formed in the left mesogastrium and is functioning. An urostoma has been formed in the right mesogastrium and is functioning. The abdomen is soft and painless at palpation in all departments (**Figure 1**).

Local status: there are three fistulas in the perineum, with a diameter from 10 mm to 13 mm, the skin around them is vividly hyperemic, infiltrated, macerated, and bleeding upon contact (**Figure 1**). In recent weeks, there has been an increase in the quantity of the loss of small intestine discharge with an admixture of pus up to 1,500 ml or more per day.

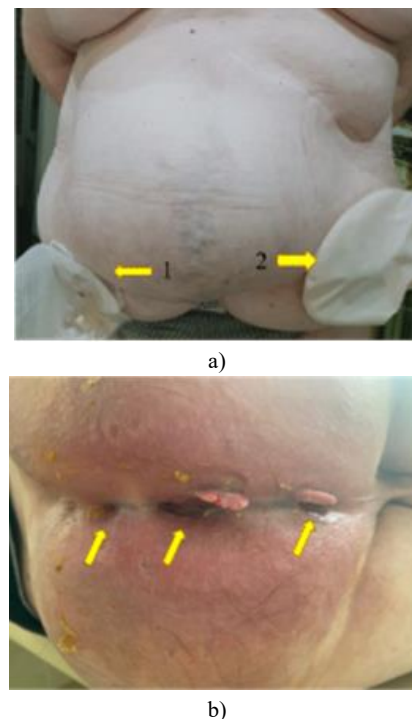


Figure 1. Photo of the anterior abdominal wall (top view): 1: urostoma, 2: functioning single-barrel descendostoma. Photo of the perineum with 3 fistula passages opening, pronounced maceration of the skin, and hypergranulations in the fistula area.

Laboratory data showed that in the general blood test, there was a decrease in hemoglobin to 97 g/l and an increase in erythrocyte sedimentation rate (ESR) to 120 mm/h.

X-ray gastro-epistolography was performed: when a water-soluble contrast was introduced through the fistula in the perineum, the cavity in the pelvis was filled with contrast (instrumental picture of an abscess), which communicated with the loop of the small intestine (**Figure 2**).

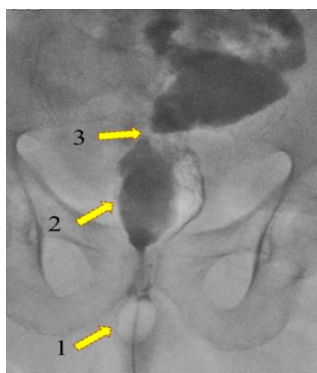


Figure 2. X-ray gastro-fistulography image (direct projection): 1: the inflated cuff of the Folley catheter inserted into the external opening of the fistula, 2: the cavity of the pelvic abscess, 3: the communication of the pelvic abscess with the loop of the small intestine.

After further examination and comprehensive preoperative preparation, surgical intervention was performed as planned.

After performing median laparotomy and splice separation, the distal part of the small intestine conduit was visualized. A further revision revealed a dense infiltrate in the pelvis involving loops of the small intestine and the distal part of the conduit. When the latter were isolated, a purulent cavity was opened, the contents of which were pus and intestinal discharge with detritus of about 100 ml (**Figure 3**).

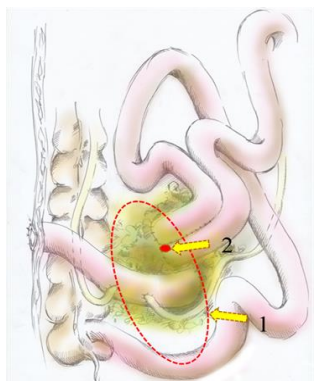


Figure 3. Schematic drawing of the location of the fistula concerning the conduit and the pelvic abscess: 1: the cavity of the abscess involving the intestinal anastomosis and conduit, 2: intestinal fistula in the intestinal anastomosis "side to side".

The cavity was sanitized with antiseptic solutions to clean water. Upon further revision, it was discovered that the distal part of the conduit and a section of the small intestine with a formed interstitial anastomosis "side to side" were the walls of the abscess cavity. In the anastomosis, there was a defect of the intestinal wall with a diameter of about 1 cm (a defect communicating with the purulent cavity) which was tightly fixed by infiltrative tissues to the conduit and the area of previously formed ureteroenteroanastomoses (**Figure 4**).

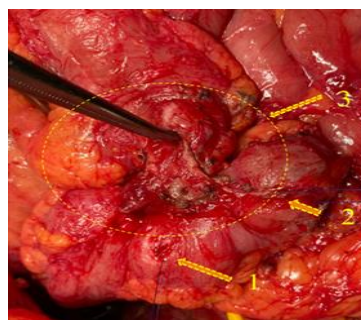


Figure 4. Photo of the interstitial anastomosis "side to side" with the defect of the latter fixed to the conduit: 1, 2: separated ureteroenteroanastomoses, 3: the fistula fixed to the conduit.

A separation of the conduit and the loop of the small intestine with the interstitial anastomosis "side to side" from the walls of the purulent cavity and each other was performed (**Figure 5**).

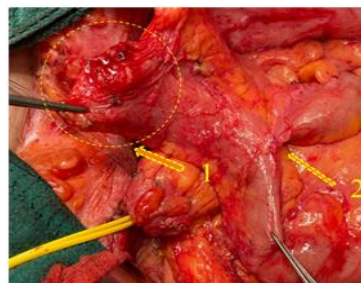

Figure 5. Photo of the interstitial anastomosis of a previously performed surgery: 1: defect in the anastomosis (intestinal fistula), 2: interstitial anastomosis "side to side".

A resection of the loop of the small intestine carrying the anastomosis "side to side" and the fistula was performed. The continuity of the small intestine was restored by end-to-end anastomosis with a single-row continuous suture. During the subsequent revision, it was noted that the distal end of the conduit was infiltrated, and the walls of the intestine and the mouths of the ureters in the area of anastomoses were compromised. It was decided to perform a resection of the altered distal portion of the conduit with reimplantation of the ureters more proximally. Ureteroenteroanastomoses were formed by separate nodular sutures with a polydioxanone (PDS) 5/0 thread on ureteral stents (**Figure 6**).

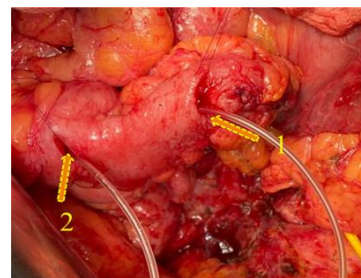


Figure 6. Photo of resected conduit: 1, 2: formation of ureteroenteroanastomoses on the loop of the small intestine.

Drainages to the area of ureteroenteroanastomoses and double-light drainage into the cavity of the abscess, through the fistula passage in the perineum, were installed. The wound was stitched tightly layer by layer. Thus, the scope of the surgery was laparotomy, adhesiolysis, resection of the interstitial anastomosis "side to side", bearing a small intestinal fistula, and resection of the conduit. Formation of a single-row continuous interstitial anastomosis of the "end-to-end" type. Formation of ureteroenteroanastomoses on ureteral stents, drainage of the abdominal cavity and pelvis minor (**Figure 7**).

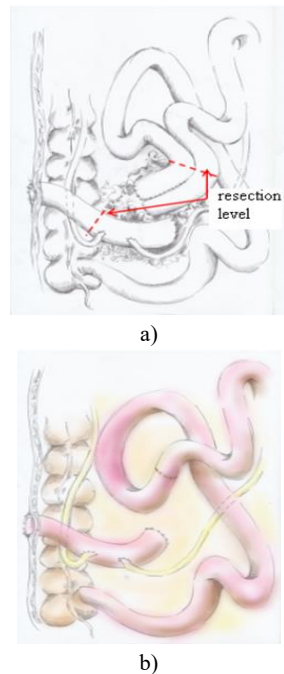


Figure 7. Preoperative scheme (a): the dotted line indicates the level of resection of the intestinal anastomosis and conduit. b) is a diagram of the final scope of the surgery.

Conclusion of the histological examination: morphological picture of the small intestine fistula, no tumor cells were found.

The postoperative period proceeded smoothly. The ureteral stents were removed on the 7th day, and the drainage from the abscess cavity was removed on the 10th day. On the 11th day, the patient was discharged under the supervision of a surgeon at his place of residence in satisfactory condition.

Results and Discussion

Patients with locally advanced rectal cancer are common and often develop specific complications after undergoing radical surgery.

Most often, the postoperative period after TPE is complicated by the occurrence of a pelvic abscess (6.1 to 12.8%), failure of ureterojejunoanastomosis with the formation of urinary fistulas (4.6%), while cases of failure of small intestine anastomosis or perforation of the small intestine are less common (3.6%) (Platt *et al.*, 2018; Yang *et al.*, 2021; Nielsen *et al.*, 2022; Shine *et al.*, 2022).

In the presence of a pelvic abscess, drainage is performed under ultrasound or computer tomography (CT) control followed by complex conservative therapy.

An indication for performing a relaparotomy with further sanitation and drainage is the early removal of drainage or the formation of an abscess in the late postoperative period with the absence of a safe route for drainage by minimally invasive methods.

In our case, we observed the formation of a pelvic abscess, due to the presence of partial insolvency of the ileoileal anastomosis.

The main symptoms of this severe complication are periodic discharge of pus and intestinal discharge into a wound or drainage channel formed due to prolonged standing of the drainage tube in the perineum area, which certainly leads to local complications of small intestine fistula, such as chemical burn and dermatitis, which was noted in this clinical case.

To date, the most informative methods of instrumental diagnosis in the presence of a complex small intestinal fistula are CT of the abdominal organs with intravenous contrast enhancement and X-ray entero-fistulography. They help to determine the localization of the small intestine fistula, estimate the length of the abducting and adducting loops of the small intestine, and identify possible complications.

The only option for radical treatment aimed at eliminating the small intestine fistula is surgery. The scope of the surgery is selective and has to be determined individually.

The formation of anastomoses of hollow organs is an important and complex part of surgery of the abdominal cavity and pelvis, especially in multi-organ resections. For their successful performance, strict adherence to the basic principles of resection and the formation of anastomoses of hollow organs is necessary. The main principles in the formation of an ileoileal anastomosis are end-to-end anastomosis, even in the presence of different diameters of the adducting and abducting intestines, contact of serous membranes, preservation of adequate blood supply in the anastomosis zone, a wide connection of the edges of the submucosal layer, which gives strength to the anastomosis, and the formation of the anastomosis without tension.

Conclusion

In this clinical case, the restoration of the continuity of the intestinal tract was carried out by the formation of an inter-intestinal anastomosis of the "side to side" type with a length of about 10 cm. This anastomosis is not physiological, and the intra-intestinal pressure put on the blind ends of the adducting and abducting intestine is maximum. Naturally, the source of the intestine fistula was the failure of the blind end of the adducting intestine with the formation of infiltrate and pelvic abscess.

Further management of the patient consisted in drawing up an adequate and consistent algorithm for performing additional examination methods and their correct interpretation, which made it possible to determine the optimal tactics for surgical treatment of the patient and obtain satisfactory results.

Acknowledgments: The authors express their gratitude to the anonymous reviewers and the editors of the journal.

Conflict of interest: None

Financial support: None

Ethics statement: The study was conducted following international ethical standards. Informed consent was obtained from all study participants.

References

- Aglullin, I. R., Didakunan, F. I., Ziganshin, M. I., Valiev, A. A., Agullin, T. I., Safin, I. R., & Agullin, M. I. (2015). Technical aspects of pelvic eviscerations. *Povolzhskii Onkologicheskii Vestnik*, 4, 63-64.
- Ajwa, N., Faya, I. S. I., Alasbali, S. H. F., Alrayes, A. O. M., Alsaif, A. A. A., & AlJahdali, S. L. H. (2022). Occurrence of cross-bite among school children in Jeddah city; an observational study. *Annals of Dental Specialty*, 10(1), 59-61. doi:10.51847/hYAQH5IQTIX
- Al-Sunbul, A. A. S., Aldhalaan, R., AlHaddab, M., & AlZahrani, F. (2022). Mandibular distraction with anterior dental implants; a case report. *Annals of Dental Specialty*, 10(1), 52-58. doi:10.51847/nC0Zf56SdU
- Appleby, L. H. (1950). Proctocystectomy: The management of colostomy with ureteral transplants. *The American Journal of Surgery*, 79(1), 57-60.
- Berman, M. L., Lagasse, L. D., Watring, W. G., Moore, J. G., & Smith, M. L. (1976). Enteroperineal fistulae following pelvic exenteration: A 10-point program of management. *Gynecologic Oncology*, 4(4), 368-374.
- Bricker, E. M., & Modlin, J. (1951). The role of pelvic evisceration in surgery. *Surgery*, 30(1), 76-94.
- Carvalho, F., Qiu, S., Panagi, V., Hardy, K., Tutchter, H., Machado, M., Silva, F., Dinen, C., Lane, C., Jonroy, A., et al. (2023). Total Pelvic Exenteration surgery-Considerations for healthcare professionals. *European Journal of Surgical Oncology*, 49(1), 225-236. doi:10.1016/j.ejso.2022.08.011
- Chidambaranathan, A. S., & Culathur, T. (2022). A prospective clinical study to evaluate the effectiveness of acupuncture treatment for temporomandibular joint muscular disorder. *Annals of Dental Specialty*, 10(1), 34-38. doi:10.51847/172V2CMsF3
- El-kordy, M., Attia, S. G., Anwar, H. W., Mohamed, I. A., Elgamal, E. R., Shalamesh, M. I., Moghazy, A. B., & Elewasy, E. A. (2019). Lateral backdoor approach versus conventional anterior approach in recurrent Thyroid surgery. *Journal of Advanced Pharmacy Education & Research*, 9(1), 7.
- Nielsen, C. K. P., Sørensen, M. M., Christensen, H. K., & Funder, J. A. (2022). Complications and survival after total pelvic exenteration. *European Journal of Surgical Oncology*, 48(6), 1362-1367. doi:10.1016/j.ejso.2021.12.472
- Peacock, O., Waters, P. S., Kong, J. C., Warrier, S. K., Wakeman, C., Eglinton, T., Heriot, A. G., Frizelle, F. A., & McCormick, J. J. (2020). Complications after extended radical resections for locally advanced and recurrent pelvic malignancies: A 25-year experience. *Annals of Surgical Oncology*, 27(2), 409-414.
- PelvEx Collaborative. (2018). Factors affecting outcomes following pelvic exenteration for locally recurrent rectal cancer. *British Journal of Surgery*, 105(6), 650-657. doi:10.1002/bjs.10734
- PelvEx Collaborative. (2019). Changing outcomes following pelvic exenteration for locally advanced and recurrent rectal cancer. *BJS Open*, 3(4), 516-520. doi:10.1002/bjs5.50153
- Platt, E., Dovell, G., & Smolarek, S. (2018). Systematic review of outcomes following pelvic exenteration for the treatment of primary and recurrent locally advanced rectal cancer. *Techniques in Coloproctology*, 22, 835-845. doi:10.1007/s10151-018-1883-1
- Sabbahi, D. A. (2022). Systematic review of different outcomes for dental treatment provided to children under general anesthesia. *Annals of Dental Specialty*, 10(1), 13-33. doi:10.51847/XjoKWslc7T
- Samara, M., Klimov, A. E., Persov, M. Y., Kirtadze, D. G., & Barhudarov, A. A. (2020). Justification of the differentiated approach to minimally invasive and open surgeries for acute pancreatitis complications. *Archives of Pharmacy Practice*, 11(2), 65-68.
- Shetty, B., Chauhan, R. S., Vishwas, P., Rath, N., Krishnapriya, N., & Tirupathi, S. (2022). Antimicrobial efficacy of curcumin modified zinc oxide eugenol against endodontic pathogens. *Annals of Dental Specialty*, 10(1), 47-51. doi:10.51847/1DcKJ12DSy
- Shine, R. J., Glyn, T., & Frizelle, F. (2022). Pelvic exenteration: a review of current issues/controversies. *ANZ Journal of Surgery*, 92(11), 2822-2828. doi:10.1111/ans.17734
- Venchiarrutti, R. L., Solomon, M. J., Koh, C. E., Young, J. M., & Steffens, D. (2019). Pushing the boundaries of pelvic exenteration by maintaining survival at the cost of morbidity. *Journal of British Surgery*, 106(10), 1393-1403.
- Verma, P., & Pandian, S. M. (2022). Prevalence of endodontically treated posteriors in patients undergoing orthodontic treatment-cross-sectional radiographic evaluation. *Annals of Dental Specialty*, 10(1), 1-6. doi:10.51847/VtxY3JqaJ5
- Wąsacz, K., & Chomyszyn-Gajewska, M. (2022). Oral health related quality of life (OHRQoL) and associated factors in adult patients. *Annals of Dental Specialty*, 10(1), 7-12. doi:10.51847/m6Xf0sPnUT
- Yang, H., Rui, Y., & Chen, H. (2021). Management of a pelvic abscess and abdominal fistula after palliative total pelvic exenteration with intraoperative radiotherapy in recurrent rectal cancer without NPWT: A case report. *Advances in Skin & Wound Care*, 34(12), 675-679. doi:10.1097/01.ASW.0000797964.31949.b4
- Yunoki, K., Yoshimitsu, M., Oshita, K., Yano, T., Kubota, T., Ishida, M., Sato, D., Choda, Y., Nakano, K., Harano, M., et al. (2020). Total pelvic exenteration and perineal reconstruction with a gracilis myocutaneous flap for local recurrence of rectal cancer. *Gan to Kagaku ryoho. Cancer & Chemotherapy*, 47(13), 2349-2351.
- Zahid, T. M., & Khan, N. S. (2022). Myrrh and chlorhexidine mouthwashes comparison for plaque, gingivitis and inflammation reduction: a 3-arm randomized controlled trial. *Annals of Dental Specialty*, 10(1), 39-46. doi:10.51847/ajwgutvUNV