

Effect of *Pimpinella anisum* and *Salvia officinalis* Extracts on Developing Liver of Chick Embryo: 14-Day Incubation

Fawzyah Abdullah Al-Ghamdi*, Rabab Mohamed Aljarari, Nouf Sulaiman Albalawi

Received: 06 June 2023 / Received in revised form: 12 September 2023, Accepted: 14 September 2023, Published online: 26 September 2023

Abstract

The present study was designed to evaluate the effects of *P. anisum* and *S. officinalis* extracts on the liver of chicken embryos. Eighty fertilized chicken eggs were divided into eight groups. The first group (C) served as a control group. The second, third, and fourth groups (P1, P2, and P3) of high, medium, and low concentrations of *P. anisum* aquatic extracts. The fifth, sixth, and seventh groups (S1, S2, and S3) of high, medium, and low concentrations of *S. officinalis* aquatic extracts. The eighth group (M) of medium concentrations of *P. anisum* and *S. officinalis* aquatic extracts. All groups were injected *in ovo* (0.1 ml/egg) of aquatic extracts before incubation and the eighth day of incubation. After 14 days of incubation, the eggs were opened and biochemical assays in liver homogenate were made. Also, histological studies were made in the liver. Results revealed that the activity of liver homogenate levels of SOD, GSH, and CAT significantly decreased in P1, S1, and M-treated chicken embryos, while significantly increasing in P2, P3, S2, and S3-treated chicken embryos. A significant increase in liver homogenate levels of MDA was observed in all treatment groups. Histological studies of the liver in medium and low concentrations showed normal structures. Furthermore, the liver sections in P1, S1, and M-treated chicken embryos showed some damage. In conclusion, high concentrations of *P. anisum* and *S. officinalis* and the combined group have negative effects on the embryo chick liver. While medium and low concentrations have positive effects due to their antioxidant constituents.

Keywords: Chick embryo liver, *Pimpinella anisum*, *Salvia officinalis*, Oxidative stress markers

Introduction

Herbs are widely used for a variety of therapeutic purposes all over the world (Faizi & Kazmi, 2017). According to a World Health Organization (WHO) survey, roughly 70-80 percent of the global population relies on non-conventional treatment, primary herbal sources (Zaitoun *et al.*, 2019; Galea-Holhos *et al.*, 2023). The incidence of herbal medicine use among Middle Eastern pregnant women ranged from 22.3 percent to 82.3 percent (John &

Fawzyah Abdullah Al-Ghamdi*, Rabab Mohamed Aljarari, Nouf Sulaiman Albalawi

Department of Biology, College of Science, University of Jeddah, Jeddah, Saudi Arabia.

*E-mail: faalgamdi@uj.edu.sa

Shantakumari, 2015). In numerous countries, traditional medicine has provided an enticing supply of natural medicines for the treatment of chronic disorders (Asadollahpoor *et al.*, 2017; Popa-Nedelcu *et al.*, 2020).

Anise (*Pimpinella anisum*) belongs to the Umbelliferae family (Shojaii & Abdollahi, 2012). *P. anisum* is an annual grassy plant and has a sweet, spicy, and aromatic flavor. It is native to the Near East and commonly farmed in countries along the Mediterranean Sea (Mohamed *et al.*, 2015; Vartolomei *et al.*, 2022). Extract of *P. anisum* seed contains trans-anethole as the major compound, estragole, eugenol, pseudo isoeugenol, methyl chavicol, o-isoeugenol, α -zingiberene, Cis-anethole, γ -himachalene, anisaldehyde, Octanol, terpene hydrocarbons, polyenes and polyacetylenes as the principal chemical components (Müller-Fabian *et al.*, 2018; Alafaria *et al.*, 2020). *P. anisum* is used to treat dyspeptic symptoms, spasmodic gastrointestinal bloating, effect on menopausal hot flashes, and upper respiratory catarrh (Al-Halaseh, 2013; Jayavel *et al.*, 2022). The aqueous extract of *P. anisum* may have a protective effect against neurological problems, especially during development (Bekara *et al.*, 2015; Singh *et al.*, 2022). This impact could be attributed to the antioxidant capacity of *P. anisum*, which was linked to their amount of bioactive chemicals (Shojaii & Abdollahi 2012). The effect of *P. anisum* can sometimes substitute estrogen in the body, resulting in cause hormone sensitivity and increased risk of cancer (Albini *et al.*, 2014; Akatli *et al.*, 2022). The harmful effect of an excessive amount of anise consumption causes hormonal imbalances and lowers the number of sperm in males (Helal *et al.*, 2019; Asfahani, 2022).

Sage (*Salvia officinalis*) is a perennial round shrub and belongs to Labiatae/Lamiaceae (Ghorbani & Esmailizadeh, 2017). *S. officinalis* is native to the Mediterranean; it is aromatic and has wonderfully colored leaves (Hamidpour *et al.*, 2014; Çakar *et al.*, 2022). The primary compounds found in *S. officinalis* flowers, leaves, and stems are eucalyptol (1,8-cineole), α -thujone, β -thujone, camphor, β -caryophyllene, α -caryophyllene (α -humulene), tannic acid, viridiflorol, manool, estrogenic substances, caffeic acid, niacin, 12-methoxycarnosinic acid, oleic acid, rosmarinic acid, cornsolic acid, ursolic acid, nicotinamide, chlorogenic acid, malic acid, ursonic acid, succinic acid, fumaric acid, tartaric acid, comsole, citric acid and Luteolin-7-O-glucuronide (Garcia *et al.*, 2016).

S. officinalis is used to treat anxiety, excessive lactation, and perspiration (Lopresti, 2017). Excessive use of *S. officinalis* might



result in a warm feeling, disorientation, tachycardia, and convulsions that are like epilepsy. *S. officinalis* raises the risk of drug interactions with diabetes and blood pressure medications (Kargozar *et al.*, 2017).

Pregnant and breastfeeding moms who use herbal remedies without understanding the risks to both mother and fetus or child may put themselves and their fetus or their infant in grave danger, including abortion, early birth, uterine hemorrhage, and physical and mental retardation fetus (Eid & Jaradat, 2020).

The liver is the body's biggest organ. It is situated between the portal and the general circulation. The liver is in charge of a variety of processes including detoxification, metabolism, immunity, digestion, and vitamin storage (Ramadori *et al.*, 2008).

Materials and Methods

The principles of animal care and use were carefully followed in this study following the guide to the care and use of laboratory animals approved by the College of Science, University of Jeddah, Saudi Arabia.

Eggs

Fertilized chicken eggs were obtained from a local farm in Jeddah City, Makkah region, Saudi Arabia.

Incubation

Eighty eggs with average weight (60-62 g) were weighed in the lab and incubated at 37 °C and 65% humidity, the incubator automatically rotates the eggs once every 90 minutes (El-Borm *et al.*, 2019).

Injection Method

Eggs were washed under high sterilization conditions and sterilized with 70% alcohol, and two holes were made parallel to each other with a sterile needle. Then, the eggs were injected with saline solution, *P. anisum* aquatic extract, *S. officinalis* aquatic extract, and their combination. Finally, holes were closed with paraffin wax.

Preparation of Plant Aquatic Extracts

P. anisum Aquatic Extract

1. The *P. anisum* seeds were washed with water to get rid of dust and left to dry for two days at room temperature with constant stirring so as not to rot.
2. The *P. anisum* seeds were ground using an electric grinder to get a fine powder.
3. 10 g of *P. anisum* seeds powder was placed into 250 ml of water and soak it for 24 hours.
4. The extract was filtered using filter paper (90 mm diameter, grade 2).

The preparation of the *P. anisum* aqueous extract was according to Alsalmi *et al.* (2016).

S. Officinalis Aquatic Extract

1. Washed the *S. officinalis* leaves to get rid of dust and let them dry.
2. 250 ml of boiling water was poured over 10 g of *S. officinalis* leaves and covered for 5 minutes.
3. The solution was filtered through a strainer.

The extract was made as a tea according to its traditional use, according to Salah *et al.* (2016).

The method in which different concentrations were made from both *P. anisum* and *S. officinalis* aquatic extracts is the dilution law for the solutions to make three concentrations for each extract (Almakhzumi *et al.*, 2015).

$$\begin{aligned} V_1C_1 &= V_2C_2 \\ V_1 &= V_2C_2/C_1 \end{aligned} \quad (1)$$

High Concentration

$$V_1 = 10 \text{ ml} * (100\%) / 100\% = 10 \text{ ml} \quad (2)$$

Medium Concentration

$$V_1 = 10 \text{ ml} * (50\%) / 100\% = 5 \text{ ml} \quad (3)$$

Low Concentration

$$V_1 = 10 \text{ ml} * (10\%) / 100\% = 1 \text{ ml} \quad (4)$$

Experimental Design

Eighty fresh fertilized chicken eggs (*Gallus domesticus*) were divided into 8 groups, each containing 10 eggs, and all received repeated doses of different concentrations of *P. anisum* and *S. officinalis* aquatic extracts before incubation and the eighth day of incubation. A total of 80 fertilized eggs were included.

1. Group C was injected *in ovo* (0.1 ml/egg) of saline solution (Control group).
2. Group P1 was injected *in ovo* (0.1 ml/egg) of high concentration of *P. anisum* aquatic extract.
3. Group P2 was injected *in ovo* (0.1 ml/egg) of medium concentration of *P. anisum* aquatic extract.
4. Group P3 was injected *in ovo* (0.1 ml/egg) of low concentration of *P. anisum* aquatic extract.
5. Group S1 was injected *in ovo* (0.1 ml/egg) of high concentration of *S. officinalis* aquatic extract.
6. Group S2 was injected *in ovo* (0.1 ml/egg) of medium concentration of *S. officinalis* aquatic extract.
7. Group S3 was injected *in ovo* (0.1 ml/egg) of low concentration of *S. officinalis* aquatic extract.
8. Group M was injected *in ovo* (0.1 ml/egg) of medium concentrations of *P. anisum* and *S. officinalis* aquatic extracts.

Collecting Embryos and Specimens

The eggs designated for the study were opened on the 14th day of incubation, and the live embryos were anesthetized using ether and dissected to remove the liver. A portion of liver tissue from all groups was collected and fixed in 10% formalin for histological studies. Also, a portion of liver tissue from all groups was frozen at -80 °C for the preparation of tissues homogenate with 0.1 M sodium phosphate buffer (pH 7.4). The frozen liver was homogenized for biochemical studies, then centrifuged for 15 min at 10,000 revolutions per minute (rpm) at 4°C. After the supernatant was separated and aliquoted, it was stored at -80 °C for biochemical assay.

Liver Oxidative Markers Estimation

Fluorometric Assay kits were used to measure malondialdehyde (MDA), superoxide dismutase (SOD), reduced glutathione (GSH), and catalase (CAT) were measured according to methods of Ohkawa *et al.* (1979), Jing and Zhao (1995), Ellman (1959), Aebi (1984), respectively.

Histological Studies

After fixation of liver tissues in formalin saline (10%) for 24 hours, they were subjected to serial alcohol dilution for dehydration. Liver tissues were immersed in paraffin, cut into 5 µm thick sections, and stained in hematoxylin and eosin (H&E) for examination by a light microscope (Humason, 1979).

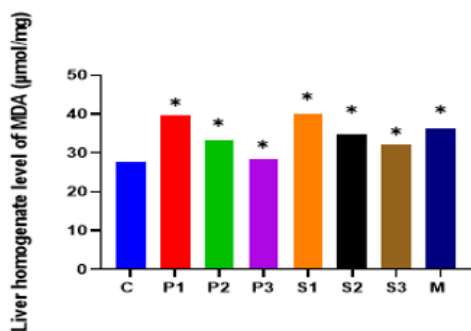
Statistical Analysis

The statistical analysis was made using Statistical Package for Social Science program, (SPSS version 25). Values expressed as mean \pm standard error. The difference between experimental groups was made using One Way ANOVA (Tukey test). *P*-value < 0.05 was recognized as a significant value.

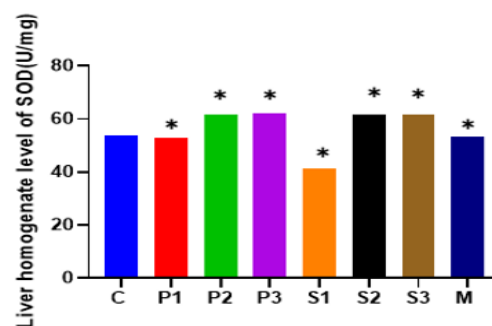
Results and Discussion

Liver Oxidative Stress Markers

The levels of MDA in the liver homogenate were significantly increased in P1, P2, P3, S1, S2, S3, and M groups compared with the control group ($P < 0.05$) (Figure 1). The levels of SOD, GSH, and CAT in the liver homogenate were significantly increased in P2, P3, S2, and S3 groups compared with the control group ($P < 0.05$) and was significantly decreased in P1, S1, and M groups compared with control group ($P < 0.05$) (Figures 1 and 2).

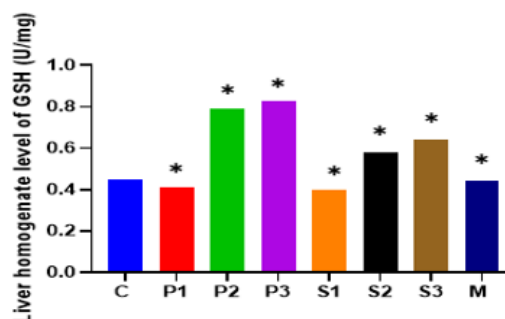


a)

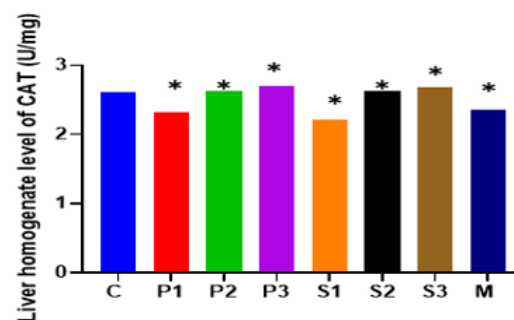


b)

Figure 1. Effects of *Pimpinella anisum* and *Salvia officinalis* aquatic extracts on MDA levels (µmol/mg) in liver homogenate and SOD levels (U/mg) in liver homogenate of 14-day-old chick embryos of different groups.



a)



b)

Figure 2. Effects of *Pimpinella anisum* and *Salvia officinalis* aquatic extracts on GSH levels (U/mg) in liver homogenate and CAT levels (U/mg) in liver homogenate of 14-day-old chick embryos of different groups.

Histological Studies

Liver

Control Group

Light microscopic observation of the control liver of 14-day-old chick embryos (C group) showed normal structure. The hepatic tissue appeared dense. The hepatic cords appeared radially

arranged and convergent around the central veins. The central veins are interspersed with narrow sinusoids with voids and irregular edges. The sinusoids are lined by endothelial cells and Kupffer cells. Also, some red blood cells were seen (**Figure 3**).

Combined Group

Comparing the histological structure of the liver of chick embryos injected with repeated doses of mid concentrations of *P. anisum* and *S.officinalis* (M group) before incubation and the eighth day of incubation revealed that some hepatocytes appear healthy and the others damaged. Furthermore, relative deformation of the cells surrounding the central veins was seen. The sinusoids were narrow and lined by endothelial cells and Kupffer cells. Also, some red blood cells were seen inside the sinuses. In addition, some hepatocytes showed degeneration (**Figure 3**).

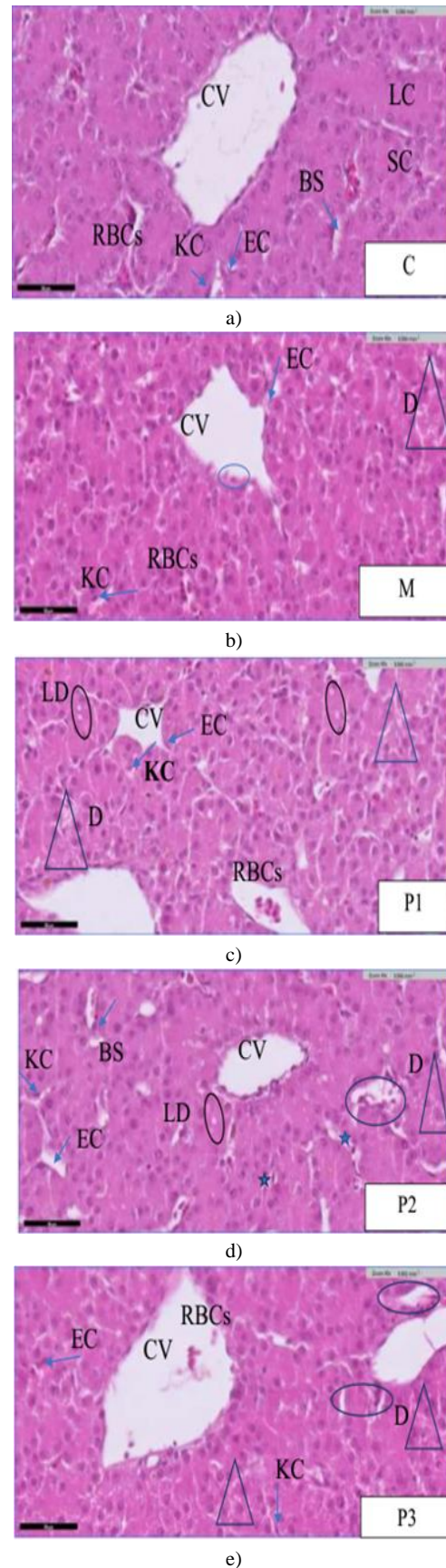
P.anisum Groups

The chick embryos injected with repeated doses of high concentration of *P. anisum* (P1 group) before incubation and on the eighth day of incubation showed hemolytic changes. The hepatocytes were radically arranged around the central vein. Red blood cells were seen inside the central vein. The sinusoids are lined by endothelial cells and Kupffer cells with relative degeneration. Moreover, lipid droplets were seen (**Figure 3**).

On the other hand, the histological structure of the liver of the groups treated with mid and low concentrations of *P. anisum* (P2 and P3 groups) before incubation and the eighth day of incubation revealed that the liver structure appeared similar to the control group. In the P2 group, relative degeneration and deformation of blood sinusoids and separation of cell lining of the sinusoids and lipid droplets were seen (**Figure 3**). While in the P3 group, relative degeneration and deformation of blood sinusoids were seen (**Figure 3**).

S.officinalis Groups

The histological structure of the liver of the group treated with a high concentration of *S.officinalis* (S1 group) before incubation and the eighth day of incubation showed that the tissue was affected and differed in its shape compared to the control group. There was congestion in the central veins. Moreover, blood sinusoids appeared congested, and the separation of cells lining the sinusoids and lipid droplets was seen. Also, the tissue revealed degeneration and pyknotic in hepatocytes (**Figure 3**). On the other hand, the histological structure of the liver of the groups treated with mid and low concentrations of *S.officinalis* (S2 and S3 groups) before incubation and the eighth day of incubation revealed that the liver structure appeared similar to the control group. Furthermore, relative degeneration and separation of the cell lining of the sinusoids and lipid droplets were seen (**Figure 3**).



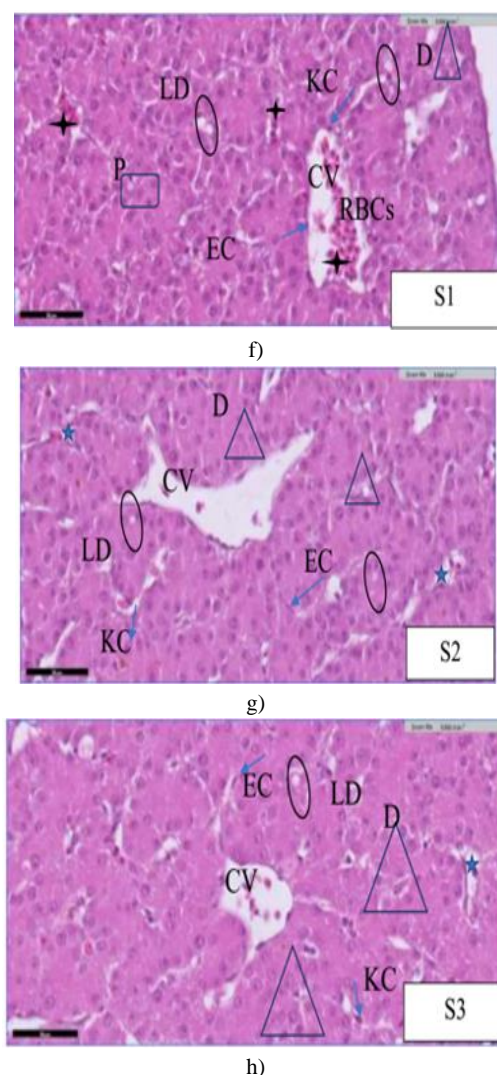


Figure 3. A photomicrograph of a transverse liver section in the 14-old chick embryo (H&E40x).

C: (control group) The hepatic cords, consisting of solid and lumenated cords, were radially arranged and convergent around the central veins, surrounded by narrow blood sinusoids and endothelial and Kupffer cells. **M:** The study reveals unclear types of hepatic chords, with some hepatocytes appearing healthy while others degenerated, and blood sinusoids were narrow with red blood cells. **P1:** The hepatic tissue showed hemolytic changes and degeneration, while lipid droplets and red blood cells were observed in the central veins. **P2:** Some hepatocytes appeared healthy, while others degenerated, causing blood sinusoids to deform, cell lining separation, and the presence of lipid droplets. **P3:** Some hepatocytes appeared healthy, and others relatively degenerated (D). Also, some deformation of blood sinusoids was seen. **S1:** Hepatic tissue exhibited hemolytic changes, including hepatocyte degeneration and pyknosis, congestion (+) in the central vein and blood sinusoids, and lipid droplets (O) in some cells. **S2** and **S3:** The hepatic tissue resembled the control group, with some sinusoids lining cells separating (*) and hepatocytes degeneration and lipid droplets observed.

Chick embryos were chosen in this study due to the lack of research on the effect of *P.anisum* and *S.officinalis* extracts on embryos in terms of morphology, histology, and physiology. The selection of chick embryos has several reasons, most notably the ease of access, incubation, and determining age (Dakhel *et al.*, 2021). The embryos were opened at the age of 14 days, and the reason for this is that from the age of 12 days, all organs have been fully developed (Abdrabou *et al.*, 2022).

Oxidative stress is caused by an imbalance between antioxidants and free radicals, which cause cellular damage (Surgucheva *et al.*, 2020). In the current study, MDA in the embryos of the experimental groups increased at age (14) days. P1 and S1-treated chicken embryos had the highest MDA levels, followed by M-treated chicken embryos. Then P2, P3, and S2, S3 treated chicken embryos. The SOD, GSH, and CAT's antioxidant levels decreased in P1, S1, and M-treated chicken embryos. Excessive ROS production that is not carefully controlled by antioxidant "detoxifying" mechanisms can potentially harm every part of the cell. MDA is a result of polyunsaturated fatty acid peroxidation brought on by ROS and is considered a typical indicator of oxidative stress (Chen *et al.*, 2015). Baldissera *et al.* (2017) reported that levels of antioxidant enzymes SOD, GSH, and CAT decreased, while MDA levels increased due to the effect of monoterpene doses in a study conducted on rat livers.

In the current study, the levels of MDA, SOD, GSH, and CAT increased at age (14) days in the P2, P3, and S2, S3 treated chicken embryos compared to the control group. Several studies reported that *P.anisum* and *S.officinalis* extracts contain flavonoids and phenolic acids compounds, which have antioxidant properties (Picon *et al.*, 2010, Sharma *et al.*, 2019). The antioxidant effects of phenolic and flavonoid molecules are mediated by the following: removing reactive nitrogen species (RNS) and ROS and preventing the creation of ROS/RNS by blocking certain enzymes or chelating trace metals involved in free radical production, and enhancing or protecting antioxidant defense (Ghasemzadeh & Ghasemzadeh, 2011).

Furthermore, our results were confirmed by histological examination that revealed the presence of an apparent effect of varying intensity in the liver sections of the chick embryos of the experimental groups. P1 and S1-treated chicken embryos had the most damage rate, followed by M-treated chicken embryos. On the other hand, the damage was minimal in the P2, P3, and S2, S3 treated chicken embryos compared to the control.

The results of a light microscopic examination of the control group showed that the liver is composed of hepatic cords arranged radially around the central vein. The central vein is interspersed with blood sinusoids lined by endothelial cells and Kupffer cells. These results were identical to previous studies (Al-Qudsi & Al-Jahdali, 2012).

Changes in the architecture of the liver are signs of toxicity and harmful effects on the organ (Singh *et al.*, 2016). In the current investigation, P1-treated chicken embryos displayed histological changes in the liver tissue portrayed by a loss in its typical structure, hepatocytes appearing distorted and undifferentiated, degeneration and pyknosis, and congested central vein. On the

other hand, P2 and P3-treated chicken embryos had significantly milder effects than P1-treated chicken embryos. These results were in agreement with a previous study (by Latifa and Mustapha, 2021), which observed hepatocyte hypertrophy with cytoplasmic vacuolation and dilation of sinusoids after injection of male mice with different doses of *P. anisum* extract (250 – 500 – 1000 mg/kg).

In the current study, S1-treated chicken embryos displayed histological changes represented by the widening of blood sinuses, blood congestion, degeneration, pyknosis, and the presence of lipid droplets. On the other hand, S2 and S3-treated chicken embryos displayed fewer histological changes than S1-treated chicken embryos. El-Ghareeb *et al.* (2016) stated that *S. officinalis* extract induces several hemorrhagic spots in rat embryos, and the major vein widens with rupture in the endothelial cells lining it, also the increase of macrophages and red blood cells. Monoterpenes are present in the *S. officinalis* oil and cause alterations in the activities of the liver and kidneys (Wojtunik-Kulesza, 2022).

Cellular degeneration can occur because of inflammatory and immunological responses by chemical compounds, parasitic and viral infections, and damaging agents against the body's cells and tissues (Al-Ghamdi *et al.*, 2017). Furthermore, lipid droplets are formed to counteract cytotoxicity (Zhang & Liu, 2018).

Conclusion

This study revealed that excessive consumption of *P. anisum* and *S. officinalis* extracts during pregnancy can have negative effects on the embryo's chick liver. Also, the effect of herbs depends on the time of the dose and the duration of its stay inside the tissue. On the other hand, low concentrations had a positive effect on antioxidant enzyme activities. It is recommended not to overconsume herbs during pregnancy. Moreover, it can be argued that the combination of *P. anisum* and *S. officinalis* extracts causes a multiplier effect, it is preferred to use the herbs separately.

Acknowledgments: This review article was part of a master thesis of N.A. The authors thank the College of Science at the University of Jeddah for their support.

Conflict of interest: None

Financial support: None

Ethics statement: Ethical was granted from the Department of Biology, College of Science, University of Jeddah, KSA ethical committee (ethical approval number: HAP-02-J-094).

References

Abdrabou, M. A., Al-Subhi, M. H., & Al-Shammari, T. M. (2022). Effect of Ferula asafetida extract on the development of chick embryo. *Bioscience Research*, *19*(4), 2060-2066.

Aebi, H. (1984). Catalase in vitro. *Methods Enzymology*, *105*, 121-126. doi:10.1016/s0076-6879(84)05016-3

Akatli, A. N., Ayva, E. S., & Bozdogan, O. (2022). p16 (INK4a), and p14 (ARF) Expressions in Carcinogenesis of Squamous

Cell Carcinoma of the Lip. *Clinical Cancer Investigation Journal*, *11*(3), 1-8.

- Alafaria, H. A., Al-Otaibia, W. R., AlGabbani, Q., Sanad, I., ALanazic, N. M. A., Al-Dogmie, A. M., & Al-Qahtanif, W. S. (2020). Induction of IRG-1 reduces reactive oxygen species production by bioactive compounds of anise (*Pimpinella Anisum* L.) on LPS-Activated macrophages. *Revista Argentina de Clínica Psicológica*, *29*(5), 1244-1253.
- Albini, A., Rosano, C., & Angelini, G. (2014). Exogenous hormonal regulation in breast cancer cells by phytoestrogens and endocrine disruptors. *Current Medicinal Chemistry*, *21*(9), 1129-1145. doi:10.2174/09298673113206660291
- Al-Ghamdi, F. (2017). Toxicity of Monosodium Glutamate on the liver of chick embryos and the effectiveness of pomegranate peel extract in reducing this toxicity (to show scientific miracles in the Quran and Sunnah). *Life Science Journal*, *14*(9), 37-60.
- Al-Halaseh, L. (2013). Some herbal medicine traditionally used in South Jordan. *Al-Azhar Journal of Pharmaceutical Sciences*, *47*(1), 63-82.
- Almakhzumi, A. A. Aldulaimy, H. H., & Jawaad, A. M. (2015). *In vivo* effect of Catharanthus roseus crude extracts on pathogenic bacteria isolated from skin infections. *Iraqi Journal of Science*, *56*(1), 656-664.
- Al-Qudsi, F., & Al-Jahdali, A. (2012). Effect of Monosodium Glutamate on Chick Embryo Development. *The Journal of American Science*, *88*(1010), 499-509.
- Alsahli, M. S., Devanesan, S., Alfuraydi, A. A., Vishnubalaji, R., Munusamy, M. A., Murugan, K., Nicoletti, M., & Benelli, G. (2016). Green synthesis of silver nanoparticles using *Pimpinella anisum* seeds: antimicrobial activity and cytotoxicity on human neonatal skin stromal cells and colon cancer cells. *International Journal of Nanomedicine*, *11*, 4439-4449. doi:10.2147/IJN.S113193
- Asadollahpoor, A., Abdollahi, M., & Rahimi, R. (2017). *Pimpinella anisum* L. fruit: Chemical composition and effect on a rat model of nonalcoholic fatty liver disease. *Journal of Research in Medical Sciences: The Official Journal of Isfahan University of Medical Sciences*, *22*, 37. doi:10.4103/1735-1995.202147
- Asfahani, A. (2022). The effect of organizational citizenship behavior on counterproductive work behavior: A moderated mediation model. *Journal of Organizational Behavior Research*, *7*(2), 143-160.
- Baldissera, M. D., Souza, C. F., Dolci, G. S., Grando, T. H., Sagrillo, M. R., Vaucher, R. A., da Luz, S. C. A., Silveira, S. O., Duarte, M. F., Duarte, T., et al. (2017). Monoterpene alpha-terpinene-induced hepatic oxidative, cytotoxic, and genotoxic damage is associated with caspase activation in rats. *Journal of Applied Biomedicine*, *15*(3), 187-195.
- Bekara, A., Hamadouche, N. A., Kahloula, K., Harouat, S., Tabbas, D., & Aoues, A. K. (2015). Effect of *Pimpinella anisum* L (aniseed) aqueous extract against lead (Pb) neurotoxicity: neurobehavioral study. *International Journal of Neuroscience and Behavioral Science*, *3*(3), 32-40.
- Çakar, S., Özyer, K., & Azizoğlu, Ö. (2022). The mediating role of emotional labor in the impact of organizational climate on

- burnout. *Journal of Organizational Behavior Research*, 7(1), 1-13.
- Chen, J., Zeng, L., Xia, T., Li, S., Yan, T., Wu, S., Qiu, G., & Liu, Z. (2015). Toward a biomarker of oxidative stress: a fluorescent probe for exogenous and endogenous malondialdehyde in living cells. *Analytical Chemistry*, 87(16), 8052-8056. doi:10.1021/acs.analchem.5b02032
- Dakhel, S., Davies, W. I. L., Joseph, J. V., Tomar, T., Remeseiro, S., & Gunhaga, L. (2021). Chick fetal organ spheroids as a model to study development and disease. *BMC Molecular and Cell Biology*, 22(1), 37. doi:10.1186/s12860-021-00374-6
- Eid, A. M., & Jaradat, N. (2020). Public Knowledge, Attitude, and Practice on Herbal Remedies Used During Pregnancy and Lactation in West Bank Palestine. *Frontiers in Pharmacology*, 11, 46. doi:10.3389/fphar.2020.00046
- El-Borm, H., Badawy, G. M., El-Nabi, S. H., El-Sherif, W., & Atallah, M. (2019). Efficacy of curcumin on sunset yellow and tartrazine induced hepatotoxicity and nephrotoxicity in the chick embryo *Gallus domesticus*. *European Journal of Pharmaceutical and Medical Research*, 6, 48-64.
- El-Ghareeb, A. W., EL-Din, E. Y. S., Omar, A. R., & Atallah, E. S. (2016). Fetuses during the gestation period. *International Journal of Advances in Life Science*, 9(3), 307-315.
- Ellman, G. L. (1959). Tissue sulfhydryl groups. *Archives of Biochemistry and Biophysics*, 82(1), 70-77.
- Faizi, N., & Kazmi, S. (2017). Universal health coverage - There is more to it than meets the eye. *Journal of Family Medicine and Primary Care*, 6(1), 169-170. doi:10.4103/jfmpc.jfmpc_13_17
- Galea-Holhoş, L. B., Delcea, C., Siserman, C. V., & Ciocan, V. (2023). Age estimation of human remains using the dental system: a review. *Annals of Dental Specialty*, 11(3), 15.
- Garcia, C. S., Menti, C., Lambert, A. P., Barcellos, T., Moura, S., Calloni, C., Branco, C. S., Salvador, M., Roesch-Ely, M., & Henriques, J. A. (2016). Pharmacological perspectives from Brazilian *Salvia officinalis* (Lamiaceae): antioxidant, and antitumor in mammalian cells. *Anais da Academia Brasileira de Ciências*, 88(1), 281-292. doi:10.1590/0001-3765201520150344
- Ghasemzadeh, A., & Ghasemzadeh, N. (2011). Flavonoids and phenolic acids: Role and biochemical activity in plants and humans. *Journal of Medicinal Plants Research*, 5(31), 6697-6703.
- Ghorbani, A., & Esmailizadeh, M. (2017). Pharmacological properties of *Salvia officinalis* and its components. *Journal of Traditional and Complementary Medicine*, 7(4), 433-440. doi:10.1016/j.jtcm.2016.12.014
- Hamidpour, M., Hamidpour, R., Hamidpour, S., & Shahlari, M. (2014). Chemistry, Pharmacology, and Medicinal Properties of Sage (*Salvia*) to Prevent and Cure Illnesses such as Obesity, Diabetes, Depression, Dementia, Lupus, Autism, Heart Disease, and Cancer. *Journal of Traditional and Complementary Medicine*, 4(2), 82-88. doi:10.4103/2225-4110.130373
- Helal, E. G. E., Abd-El-Aziz, M. A., & Ahmed, S. S. (2019). Effect of anise (*Pimpinella Anisum* L.) as phytoestrogen on some sex hormones and biochemical parameters. *Egyptian Journal of Hospital Medicine*, 75(1), 1918-1922.
- Humason, G. L. (1979). Animal tissue techniques. San Francisco: Freeman, 661 p.
- Jayavel, K., & Sivagnanam, S. (2022). The Current Scenario Regarding the Narrative Advancement of Oral Cancer. *Clinical Cancer Investigation Journal*, 11(2), 7-13.
- Jing, T., & Zhao, X. (1995). The improved pyrogallol method by using a terminating agent for superoxide dismutase measurement. *Progress in Biochemistry and Biophysics*, 22(1), 84-86.
- John, L. J., & Shantakumari, N. (2015). Herbal Medicines Use During Pregnancy: A Review from the Middle East. *Oman Medical Journal*, 30(4), 229-236. doi:10.5001/omj.2015.48
- Kargozar, R., Azizi, H., & Salari, R. (2017). A review of effective herbal medicines in controlling menopausal symptoms. *Electronic Physician*, 9(11), 5826-5833. doi:10.19082/5826
- Latifa, F., & Mustapha, K. (2021). Evaluation of acute and subacute oral toxicities of aqueous seed extract of *Pimpinella anisum* L. In male mice evaluation des toxicite s orales aigue et subaigue de l' Extrait aqueux des graines de *Pimpinella anisum* L. *Chez Les Souris Male*, 11, 2682-2691.
- Lopresti A. L. (2017). *Salvia* (Sage): A Review of its Potential Cognitive-Enhancing and Protective Effects. *Drugs in R&D*, 17(1), 53-64. doi:10.1007/s40268-016-0157-5
- Mohamed, H. S. A., Abdelgadir, W. S., & Almagboul, A. Z. I. (2015). *In vitro* antimicrobial activity of Anise seed (*Pimpinella anisum* L.). *International Journal of Advanced Research*, 3(1), 359-367.
- Müller-Fabian, A., Siserman, C., Aniţan, Ş. M., & Delcea, C. (2018). Juvenile delinquency in light of data recorded at the Institute of Forensic Medicine. *Romanian Journal of Legal Medicine*, 26(1), 70-75.
- Ohkawa, H., Ohishi, N., & Yagi, K. (1979). Assay for lipid peroxides in animal tissue by thiobarbituric acid reaction. *Analytical Biochemistry*, 95, 351-358.
- Picon, P. D., Picon, R. V., Costa, A. F., Sander, G. B., Amaral, K. M., Aboy, A. L., & Henriques, A. T. (2010). A randomized clinical trial of a phytotherapeutic compound containing *Pimpinella anisum*, *Foeniculum vulgare*, *Sambucus nigra*, and *Cassia augustifolia* for chronic constipation. *BMC Complementary and Alternative Medicine*, 10(1), 1-9.
- Popa-Nedelcu, R., Delcea, C., Siserman, C., & Carmen Domnariu, D. C. (2020). The relationship between personality disorders and domestic violence in forensic context. *Romanian Journal of Legal Medicine*, 28(2), 166-171.
- Ramadori, G., Moriconi, F., Malik, I., & Dudas, J. (2008). Physiology and pathophysiology of liver inflammation, damage and repair. *Journal of Physiology and Pharmacology*, 59(Suppl 1), 107-117.
- Salah, M. A. C., Hussein, M., Rana, I., & Khalid, L. B. (2016). Effect of *Salvia officinalis* L. (Sage) aqueous extract on liver and testicular function of diabetic albino male rats. *Journal of University of Babylon for Pure and Applied Sciences*, 24(4), 83-90.

- Sharma, Y., Fagan, J., & Schaefer, J. (2019). Medicinal properties of Garden sage (*Salvia officinalis* L.). *Journal of Pharmacognosy and Phytochemistry*, 8(3), 3139-3148.
- Shojaii, A., & Abdollahi Fard, M. (2012). Review of Pharmacological Properties and Chemical Constituents of *Pimpinella anisum*. *ISRN Pharmaceutics*, 2012, 510795. doi:10.5402/2012/510795
- Singh, G., Goel, N., Singh, A., & Gera, R. (2022). Study of Factors Affecting the Time to Diagnosis and Treatment in Pediatric Acute Leukemia Patients-A study from India. *Clinical Cancer Investigation Journal*, 11(3), 35-40.
- Singh, T., Ruchi, K. R., Kumar, V., & Singh, A. (2016). Evaluation of biochemical and histological effects on the liver of Swiss albino mice due to acute oral toxicity of aqueous leaf extract of *Phyllanthus niruri*. *International Journal of Pharmaceutical and Phytopharmacological Research*, 8(1), 85-90.
- Surgucheva, I., Sharov, V. S., & Surgucheva, A. (2020). Synuclein: Seeding of synuclein aggregation and transmission between cells. *Biochemistry*, 51, 4743-4754.
- Vartolomei, L., Cotruș, A., Stanciu, C., Delcea, C., Tozzi, M., Lievore, E., Crocetto, F., Del Giudice, F., Lucarelli, G., Muto, M., et al. (2022). Quality of life and psychological distress among patients with small renal masses. *Journal of Clinical Medicine*, 11(14), 3944.
- Wojtunik-Kulesza, K. A. (2022). Toxicity of selected monoterpenes and essential oils rich in these compounds. *Molecules*, 27(5), 1716.
- Zaitoun, M. F., Al-Nowis, M. E., Alhumaidhan, F. Y., & Khalil, H. E. (2019). Use of herbs among pregnant women in Saudi Arabia: A cross-sectional study. *Journal of Pharmaceutical Sciences and Research*, 11(5), 2105-2108.
- Zhang, X., & Liu, P. (2018). Lipid droplet proteins and metabolic diseases. *Biochimica et Biophysica Acta - Molecular Basis of Disease*, 1864(5), 1968-1983.